

Cushing's Syndrome From Pituitary Microadenoma and Pulmonary Nodules

Dan Louie Renz P. Tating, BSN, RN, Natasha Denise S. Montevirgen, BSN, RN, and Loyda Amor N. Cajucom, MAN, RN

Tating and Montevirgen are BSN graduates in the College of Nursing at the University of the Philippines Manila, and Cajucom is an adjunct faculty member in the Faculty of Management and Development Studies at the University of the Philippines Open University.

No financial relationships to disclose.

Tating can be reached at dptating@up.edu.ph, with copy to editor at ONFEditor@ons.org.

Key words: Cushing's syndrome; pituitary microadenoma; pediatric oncology; Filipino

ONF, 43(2), 136–140.

doi: [10.1188/16.ONF.136-140](https://doi.org/10.1188/16.ONF.136-140)

A 13-year-old Filipino male patient named T.F. presented with a one-week history of bilateral lower extremity weakness, hyperkalemia, and hypertension (~140/100 mmHg), leading to hospital admission. He was started on antihypertensives and discharged three days later. His symptoms persisted and bilateral pedal edema developed. An underlying hormone dysfunction was suspected, and additional investigations revealed normal thyroid function, increased adrenocorticotropic-releasing hormone (ACTH), and persistently elevated serum cortisol. He was readmitted to a tertiary hospital. His medical history was unremarkable and included chicken pox as a young child and stunting of growth two years prior to admission, which at the time was not perceived as significant.

Functional health assessment revealed the need for some assistance and/or supervision when performing self-care. His sleep was frequently interrupted by procedures. He described himself as “sad” because of his hospitalization, verbalized missing his family and friends, and cried easily. He tensed when he thought something bad would happen to him, and used prayer to help himself cope. He and his family viewed religion as a significant factor in their life.

Physical examination revealed normal vital signs with an irregular

pulse rhythm. However, monitoring revealed hypertensive spikes with periods of tachypnea and isolated premature ventricular contractions on electrocardiogram.

T.F. reported pain to his upper back, rating it as a 4 on a 10-point visual analog scale. His body mass index was 25.04 kg/m² (overweight) and truncal obesity was visible. His skin showed good turgor but was thin, dry, and scaly in texture, with acne and hirsutism. He had a poorly healing wound (1 x 1 cm), several reddish-purple striae, and grade 1 pitting edema on his bilateral lower extremities. His nails were pale with smooth, thickened texture. Moon facie and a supraclavicular fat pad also were observed. Chest assessment revealed decreased expansion and breath sounds, with occasional rhonchi and crackles in his left lung. Extremities were thin but with good muscle tone and coordination. Ano-genital assessment revealed undescended testes and a micropenis.

Blood tests showed increased ACTH and cortisol levels, hypokalemia, increased random blood sugar, increased alanine aminotransferase, hypomagnesemia, and hypertriglyceridemia. Free T4 and thyroid stimulating hormone (TSH) were within normal values. Complete blood count revealed increased white blood cell counts with elevated neutrophils and decreased lymphocytes and low levels of red blood

cells, hematocrit, and hemoglobin. Glycosuria and bacteria were noted in the urinalysis.

Magnetic resonance imaging revealed a rounded region (0.8 x 0.9 x 0.8 cm) on the anterior pituitary gland. Ultrasonography revealed no organomegaly. A cervical/thoracolumbar spine x-ray revealed osteopenia with decreased bone density and various degrees of compression deformities, most severe at mid- to lower-thoracic levels. An abdominal computed tomography scan with IV contrast showed the presence of multiple pulmonary nodules in the right lung, mild bilateral pleural effusion, and atelectasis of the left lower lobe. The adrenal glands were normal in appearance.

Upon diagnosis of a pituitary microadenoma, transsphenoidal adenectomy was indicated but deferred because the dexamethasone suppression test revealed elevated serum cortisol and 24-hour free urine cortisol. A needle biopsy (cell block and immunoassay) confirmed the pulmonary nodules as Cushing's syndrome (CS). Before T.F. could have surgery or be discharged home, his respiratory status deteriorated and his immunocompromised state led to reactivation of the chicken pox virus. Toxins in the blood caused inflammatory reactions and systemic activation of the clotting cascade, eventually triggering disseminated intravascular coagulation (DIC). T.F. died as a result of septic shock, DIC, and acute respiratory distress syndrome.

Cushing's Syndrome

CS is a state of cortisol excess, possibly from a tumor in the pituitary gland, the adrenal gland, or an ectopic nonpituitary ACTH-secreting source. The first form, pituitary in origin, was originally described by Harvey Cushing, MD, and was labeled as Cushing's dis-

ease (CD). Long-term therapy with glucocorticoids also can lead to iatrogenic CS (Grossman & Porth, 2014).

Pituitary tumors are classified according to etiology (primary and secondary), secreting ability (functional or nonfunctional), and size. Microadenomas are less than 10 mm in size and do not cause the pituitary gland to enlarge. Macroadenomas are greater than 10 mm in size and affect surrounding cranial structures. Functional adenomas are further classified according to the hormones secreted, with 13% of pituitary adenomas secreting ACTH (Grossman & Porth, 2014). Other ACTH-secreting tumors that have been reported include intracavernous ectopic adenomas (Koizumi et al., 2011; Srikantha, Khanapure, Mohan, & Varma, 2012), pancreatic neuroendocrine tumors (Rajeev et al., 2014; Sauer et al., 2014), olfactory neuroblastoma (Mayur, Bordoni, Locandro, & McLaughlin, 2014), small cell carcinoma (Shamanic, Nudelman, Nalini, Kim, & Samson, 2010), and bronchial carcinoid (Kenchaiyah & Hyer, 2012).

Release of glucocorticoids, mainly cortisol, is regulated by the negative-feedback mechanism of the hypothalamic-pituitary-adrenal (HPA) system (see Figure 1). The hypothalamus releases corticotropin-releasing hormone to stimulate the anterior pituitary gland to secrete ACTH. ACTH then stimulates the adrenal cortex to produce cortisol, which is then carried to the various target tissues. The negative-feedback system inhibits the hypothalamus and anterior pituitary in response to elevated cortisol levels.

Incidence and Pathophysiology

Brain tumors are the leading cause of cancer death in children younger than age 20 years in the United States (American Brain Tumor Association, 2014). Pri-

mary malignant and non-malignant brain tumors occur in 5.37 cases per 100,000, with incidence rates higher in males (5.61) than females (5.11) (Central Brain Tumor Registry of the United States, 2015). Pituitary and craniopharyngeal duct tumors are the fifth most common, with an age-adjusted incidence rate of 41% among the different brain and central nervous system tumors in children aged 0–14 years. The highest incidence (67%) occurs in children aged 10–14 years (Ostrom et al., 2015). Pituitary adenomas are the most common cause of pituitary hormone hypersecretion in adults with pituitary microadenoma, causing ACTH excess in at least 90% of patients with CS (Arlt, 2015).

Other than pituitary adenomas, ectopic ACTH production accounts for less than 1% of cases of CS in adolescents. Sources of ectopic ACTH include small cell carcinoma of the lung and carcinoid tumors in the bronchus (Stratakis, 2012). In addition, Hauso et al. (2008), using the National Cancer Institute's Surveillance, Epidemiology, and End Results data, found neuroendocrine tumors (NET) of bronchopulmonary origin as the most common NET in the United States, accounting for 1%–2% of lung malignancies in adults.

A study in the Philippines by Lo, Cabradilla, Lim, and Jimeno (2014) showed that 42% of cases of CS were caused by pituitary adenoma, adrenal adenoma (36%), and ectopic ACTH-producing tumor in the lungs, pancreas, and thymus (21%). Cases in females were more common (90%).

Pituitary adenomas/microadenomas have a secretory effect on the pituitary gland, leading to increased release of ACTH and CD. In some cases, extrapituitary ACTH-secreting tumors can also cause CS. Existence of both (the pituitary microadenoma and the extrapituitary ACTH-secreting tumor)

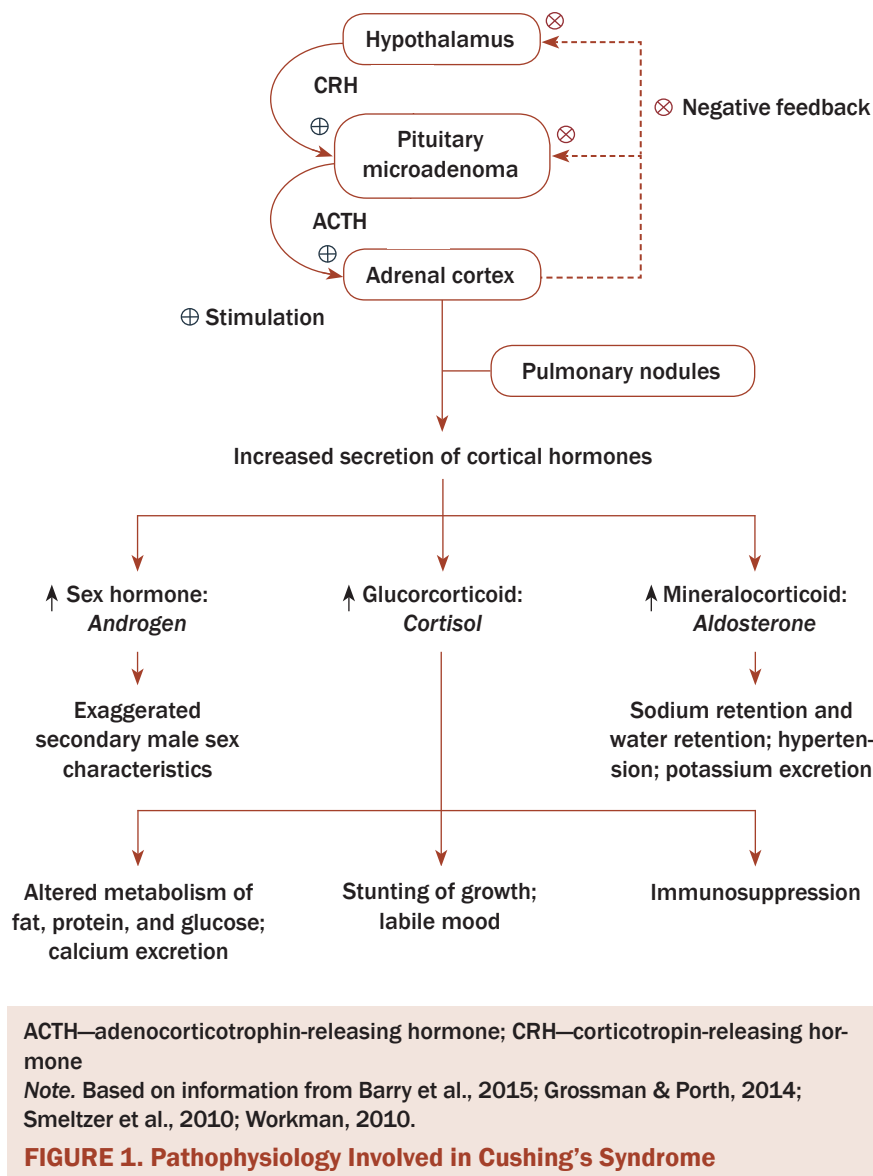


FIGURE 1. Pathophysiology Involved in Cushing's Syndrome

can, therefore, lead to a more rapid onset and progression of CS. The pathophysiology of CS is representative of an exaggerated action of cortisol. Cortisol exerts influence on glucose metabolism (stimulates gluconeogenesis and decreased glucose use of tissue), increases protein metabolism and fat metabolism, prevents anti-inflammatory action, reduces phagocytosis, suppresses the immune response, and affects psychological status (causes emotional instability).

In patients with CS, altered fat metabolism causes increased fat deposition resulting in central obesity, subclavicular fat pads,

and rounded moon facie. Protein breakdown causes muscle weakness, thinning extremities, and parchment-like skin, resulting in purple striae formation. Osteoporosis, back pain, and vertebral compression fractures manifest from destruction of bone proteins and altered calcium metabolism (Grossman & Porth, 2014). Nephrolithiasis also is reported (Valassi, Crespo, Santos, & Webb, 2012).

Mineralocorticoid properties of cortisol pose high cardiovascular risk for patients with CS, causing excessive potassium excretion (leading to hypokalemia) and sodium retention (leading to hyper-

tension). Increased cardiovascular risk in patients with CS is related to adipokines in central fat accumulation. In the active phase of the disease, proinflammatory cytokines (tumor necrosis factor- α and interleukin 6) also are observed. Angiotensinogen, the precursor of vasoactive peptide angiotensin II, and plasminogen-activating inhibitor-1 also are increased, causing vasoconstriction and further thrombus formation, respectively (Valassi, Biller, Klibanski, & Misra, 2012).

An accompanying increase in adrenal androgens causes hirsutism, mild acne, and menstrual irregularities in women. Inhibition of the inflammatory and immune responses predispose patients to infection. In addition to physical changes, behavioral and psychological changes also may occur (Grossman & Porth, 2014), with depression as the most prevalent psychological disturbance reported in about 50%–70% of the cases (Sonino, Fallo, & Fava, 2010; Tang, O'Sullivan, Diamond, Gerard, & Campbell, 2013).

Treatment Modalities

Surgical management: Transsphenoidal adenomectomy via the transnasal approach is the recommended treatment for CD (Juszczak & Grossman, 2013). However, remission rates for pituitary micro and macroadenomas are 65%–90% and 45%–60%, respectively. Post-surgery, patients need cortisol replacement because of the lack of recovery of the HPA (Biller et al., 2008). Complications include diabetes insipidus, cerebrospinal fluid leakage, vascular complications, and hypopituitarism (Rizk, Honegger, Milian, & Psaras, 2012). Diabetes insipidus occurs because of the absence of antidiuretic hormone secretion following the removal of the pituitary gland. The kidneys become unable to concentrate urine, resulting in polyuria and

diluted urine (Schreckinger, Szerlip, & Mittal, 2012).

Radiotherapy is the second line of treatment to control tumor growth and normalize hormonal secretion. This usually is delivered by external beam radiation or, alternatively, with stereotactic radiosurgery (gamma knife). Complications include hypopituitarism (Rizk et al., 2012), optic neuropathy, secondary brain tumors, and necrotic brain injury (Juszczak & Grossman, 2013).

Bilateral adrenalectomy provides definitive control of hypercortisolemia in patients with severe CS (after failure of transsphenoidal surgery or poor tolerance of medical regimen). Post-surgery, lifelong supplementation of cortisol and mineralocorticoids to control permanent hypoadrenalism is needed (Rizk et al., 2012).

Pharmacologic management: Medications are used to control elevated glucocorticoid levels in patients in remission. Pituitary-targeting drugs, such as cabergoline, pasireotide, and retinoic acid, act by binding to the dopamine receptor subtype 2 and somatostatin receptor subtype 5 to inhibit ACTH production by the adenoma. Adrenal-targeting drugs, such as ketoconazole, fluconazole, metyrapone, mitotane, and etomidate, inhibit adrenal gland steroid production. Finally, glucocorticoid receptors are blocked by mifepristone, with an affinity 18 times greater than cortisol (van der Pas, de Herder, Hfland, & Feelders, 2013).

Implications for Nursing

With CS, normalization of the negative metabolic effects and biochemical abnormalities is critical. Nursing care will include monitoring of blood results, as well as thorough physical assessments and evaluation of interventions and outcomes. In addition to the physical effects of CS, nurses must also

be cognizant of the emotional and psychological impact that CS has on adolescent patients.

One of the primary concerns in adolescents diagnosed with any form of cancer is quality of life, which is impaired in patients with CS depending on etiology and treatments (Sonino et al., 2010). Quality-of-life measures tend to improve within three years of surgery, but physical deterioration causes quality of life to get worse again over time (Lindsay, Nansel, Baid, Gumowski, & Nieman, 2006). The estimated five-year survival rate with untreated Cushing's disease involving patients with ACTH-secreting pituitary adenoma is 50%, resulting from vascular disease, stroke, myocardial infarction, uncontrolled diabetes mellitus, and infection (Clayton, 2010). Therefore, in addition to focusing on quality-of-life measures in this patient population, the timely initiation of palliative care may be a factor.

Palliative care for adolescents and young adults depends largely on their developmental stage and the issues they face regarding identity, body image, peer relations, and sexuality. Cancer disrupts normal socialization, shrinks social networks, and has the potential to destroy a patient's prior identity (Waldman & Wolfe, 2013). An adolescent faced with CS becomes predisposed to developmental and situational crises posed by the illness. The provision of psychosocial care is essential in the management of adolescent clients with CS.

Spirituality and religion as coping mechanisms were evident in T.F. and his family, particularly near the end of life. Studies have shown that spiritual well-being in patients with cancer is associated with lower levels of depression, protection against despair, and better quality of life near death (Breitbart, 2002; Greenstein & Breitbart, 2000; Puchalski, 2012). Religion is

CLINICAL HIGHLIGHTS

Cushing's Syndrome From Pituitary Microadenoma and Pulmonary Nodules

- Pituitary microadenomas and pulmonary nodules produce adrenocorticotropin-releasing hormone (ACTH), which stimulates the adrenal gland to secrete corticosteroids. This increased level of cortisol results in Cushing's syndrome (CS). Multi-system manifestations of CS result from the hypothalamic-pituitary-adrenal system.
- Medical management of CS include transsphenoidal adenomectomy, radiotherapy, and bilateral adrenalectomy. Various medications, such as pituitary-targeting drugs and adrenal-targeting drugs, can serve as adjunct treatment (van der Pas, de Herder, Hfland, & Feelders, 2013).
- Quality of life in patients (often adolescents) with pituitary microadenoma and pulmonary nodules causing CS can be greatly affected. Nurses must be able to assess and intervene when quality of life becomes compromised.
- CS is associated with multiple psychiatric and psychological disturbances, most commonly emotional lability, depression, and/or anxiety (Stratakis, 2012).

found to help people find hope in the midst of despair as well as aid in reframing their distress (Puchalski, 2012). As part of a holistic care model, nurses should also attend to a client's spiritual needs and resources to promote quality of life across the trajectory of the cancer treatment.

Conclusion

CS secondary to pituitary microadenoma and pulmonary nodules represents a complex metabolic condition with broad and pervasive impact on patients and their quality of life. Oncology nurses must provide care that is comprehensive

and meets the individual needs of each patient.

References

- American Brain Tumor Association. (2014). Brain tumor statistics. Retrieved from <http://www.abta.org/about-us/news/brain-tumor-statistics/>
- Arlt, W. (2015). Disorders of the adrenal cortex. In D.L. Kasper, S.L. Hauser, J.L. Jameson, A.S. Fauci, D.L. Longo, and J. Loscalzo (Eds.), *Harrison's principles of internal medicine* (p. 2314). New York, NY: McGraw-Hill Education.
- Barry, A., Connelly, E., & Brill, P. (2015). The child with endocrine dysfunction. In M.J. Hockenberry and D. Wilson (Eds.), *Wong's nursing care of infants and children* (10th ed., p. 1493). Maryland Heights, MO: Mosby Elsevier.
- Billir, B.M., Grossman, A.B., Stewart, P.M., Melmed, S., Bertagna, X., Bertherat, J., . . . Boscaro, M. (2008). Treatment of adrenocorticotropin-dependent Cushing's syndrome: A consensus statement. *Journal of Clinical Endocrinology and Metabolism*, *93*, 2454–2462. doi:10.1210/jc.2007-2734
- Breitbart, W. (2002). Spirituality and meaning in supportive care: Spirituality- and meaning-centered group psychotherapy interventions in advanced cancer. *Supportive Care in Cancer*, *10*, 272–280. doi:10.1007/s005200100289
- Central Brain Tumor Registry of the United States. (2015). *2015 CBRUS fact sheet*. Retrieved from <http://cbtrus.org/factsheet/factsheet.html>
- Clayton, R.N. (2010). Mortality in Cushing's disease. *Neuroendocrinology*, *92*(Suppl. 1), 71–76. doi:10.1159/000315813
- Greenstein, M., & Breitbart, W. (2000). Cancer and the experience of meaning: A group psychotherapy program for people with cancer. *American Journal of Psychotherapy*, *54*, 486–500.
- Grossman, S.C., & Porth, C.M. (2014). *Porth's pathophysiology: Concepts of altered health states* (9th ed.). Philadelphia, PA: Lippincott Williams and Wilkins.
- Hauso, O., Gustafsson, B.I., Kidd, M., Waldum, H.L., Drozdov, I., Chan, A.K., & Modlin, I.M. (2008). Neuroendocrine tumor epidemiology: Contrasting Norway and North America. *American Cancer Society*, *13*, 2655–2664. doi:10.1002/cncr.23883
- Juszczak, A., & Grossman, A.B. (2013). Cushing's disease: Current trends in treatment. *Clinical Practice*, *10*, 713–722.
- Kenchaiiah, M., & Hyer, S. (2012). Cushing's syndrome due to ectopic acth from bronchial carcinoid: A case report and review. *Case Reports in Endocrinology*. Retrieved from <http://www.hindawi.com/journals/crie/2012/215038/>
- Koizumi, M., Usui, T., Yamada, S., Fujisawa, I., Tsuru, T., Nanba, K., . . . Shimatsu, A. (2011). Successful treatment of Cushing's disease caused by ectopic intracavernous microadenoma. *Pituitary*, *14*, 295–298. doi:10.1007/s11102-008-0156-9
- Lindsay, J., Nansel, T., Baid, S., Gumowski, J., & Nieman, L. (2006). Long-term impaired quality of life in Cushing's syndrome despite initial improvement after surgical remission. *Journal of Clinical Endocrinology and Metabolism*, *91*, 447–453. doi:10.1210/jc.2005-1058
- Lo, T.E.N., Cabradilla, J.M., Lim, S.A., & Jimeno, C.A. (2014). Endogenous Cushing's syndrome: The Philippine general hospital experience. *Journal of Solid Tumors*, *4*, 1–10.
- Mayur, N., Bordonni, R.E., Locandro, D., & McLaughlin, M. (2014). Cushing's syndrome due to ectopic adrenocorticotrophic hormone production by olfactory neuroblastoma. *Endocrine Practice*, *20*, e47–e52. doi:10.4158/EP13007.CR
- Ostrow, Q., de Blank, P.M., Kruchko, C., Petersen, C.M., Liao, P., Finlay, J.L., . . . Barnholtz-Sloan, J.S. (2015). Alex's Lemonade Stand Foundation infant and childhood primary brain and central nervous system tumors diagnosed in the United States in 2007–2011. *Neuro-Oncology*, *16*(Suppl. 10), x1–x36. doi:10.1093/neuonc/nou327
- Puchalski, C.M. (2012). Spirituality in the cancer trajectory. *Annals of Oncology*, *23*(Suppl. 3), 49–55. doi:10.1093/annonc/mds088
- Rajeev, S.P., McDougall, S., Terlizzo, M., Palmer, D., Daousi, C., & Cuthbertson, D.J. (2014). Evolution in functionality of a metastatic pancreatic neuroendocrine tumor (pNET) causing Cushing's syndrome: Treatment response with chemotherapy. *BMC Endocrine Disorders*, *14*, 70. doi:10.1186/1472-6823-14-70
- Rizk, A., Honegger, J., Milian, M., & Psaras, T. (2012). Treatment options in Cushing's disease. *Clinical Medicine Insights: Oncology*, *6*, 75–84.
- Sauer, N., Zu Wiesch, C.S., Flitsch, J., Saeger, W., Klultman, S., Zustin, J., . . . Aberle, J. (2014). Cushing's syndrome due to a corticotrophin-releasing hormone- and adrenocorticotrophic hormone-producing neuroendocrine pancreatic tumor. *Endocrine Practice*, *20*, e53–e57. doi:10.4158/EP13001.CR
- Schreckinger, M., Szerlip, N., & Mittal, S. (2012). Diabetes insipidus following resection of pituitary tumors. *Clinical Neurology and Neurosurgery*, *115*, 121–126. doi:10.1016/j.clineuro.2012.08.009
- Shamanic, S., Nudelman, R.J., Nalini, R., Kim, H.S., & Samson, S.L. (2010). Ectopic corticotropin-releasing hormone (CRH) syndrome from metastatic small cell carcinoma: A case report and review of the literature. *Diagnostic Pathology*, *5*, 56. doi:10.1186/1746-1596-5-56
- Smeltzer, S.C., Bare, B.G., Hinkle, J.L., & Cheever, K.H. (2010). *Brunner and Sudarth's textbook of medical-surgical nursing* (12th ed.). Philadelphia, PA: Lippincott Williams and Wilkins.
- Sonino, N., Fallo, F., & Fava, G.A. (2010). Psychosomatic aspects of Cushing's syndrome. *Review of Endocrine Metabolic Disorders*, *11*, 95–104.
- Srikantha, U., Khanapure, K., Mohan, M., & Varma, R.G. (2012). Sphenoidal ectopic ACTH-secreting pituitary adenoma. *Journal of Pakistani Medical Studies*, *2*, 59–62.
- Stratakis, C.A. (2012). Cushing syndrome in pediatrics. *Endocrinology and Metabolism Clinics of North America*, *41*, 793–803. doi:10.1016/j.ecl.2012.08.002
- Tang, A., O'Sullivan, A.J., Diamond, T., Gerard, A., & Campbell, P. (2013). Psychiatric symptoms as a clinical presentation of Cushing's syndrome. *Annals of General Psychiatry*, *2013*, 12–23. doi:10.1186/1744-859X-12-23
- Valassi, E., Billir, B.M., Klisanski, A., & Misra, M. (2012). Adipokines and cardiovascular risk in Cushing's syndrome. *Neuroendocrinology*, *95*, 187–206. doi:10.1159/000330416
- Valassi, E., Crespo, I., Santos, A., & Webb, S.M. (2012). Clinical consequences of Cushing's syndrome. *Pituitary*, *15*, 319–329. doi:10.1007/s11102-012-0394-8
- van der Pas, R., de Herder, W.W., Hfland, L.J., & Feelders, R.A. (2013). Recent developments in drug therapy for Cushing's disease. *Drugs*, *73*, 907–918. doi:10.1007/s40265-013-0067-6
- Waldman, E., & Wolfe, J. (2013). Palliative care for children with cancer. *Nature Reviews. Clinical Oncology*, *10*, 100–107.
- Workman, M.L. (2010). Care of patients with pituitary and adrenal gland problems. In D.D. Ignatavicius and M.L. Workman (Eds.), *Patient-centered collaborative care approach to medical-surgical nursing* (6th ed., pp. 1266–1284). Singapore: Elsevier Pte Ltd.

Authorship Opportunity

Clinical Challenges provides readers with a forum to discuss creative clinical solutions to challenging patient care issues. Case studies or descriptions may be submitted with or without discussion or solutions. Materials or inquiries should be directed to Associate Editor Erin Streu, RN, MN, CON(C), at erin.streu@cancercares.mb.ca.