



# Stiff Person Syndrome: A Case Report

Patricia A. Kelly, DNP, APRN, CNS, AOCNP®, and Carolyn Kuberski, BSN, RN, OCN®

The case report features a patient who had a diagnosis of a common type of breast cancer with an uncommon neurologic syndrome. She had extreme pain and progressive stiffness with cognitive and functional decline. This article includes the pathogenesis and treatment options for a rare, but treatable, autoimmune disorder of malignancy called stiff person syndrome.

Patricia A. Kelly, DNP, APRN, CNS, AOCNP®, is a nurse translationist of evidence-based practice and research and a genomics consultant and Carolyn Kuberski, BSN, RN, OCN®, is a nursing supervisor of inpatient and outpatient oncology, both at the Texas Health Presbyterian Hospital Dallas. The authors take full responsibility for the content of the article. The authors did not receive honoraria for this work. No financial relationships relevant to the content of this article have been disclosed by the authors or editorial staff. Kelly can be reached at [patriciakelly@texashealth.org](mailto:patriciakelly@texashealth.org), with copy to editor at [CJONEditor@ons.org](mailto:CJONEditor@ons.org).

Key words: paraneoplastic syndrome; neurological; auto-immune; malignancy; stiff person

Digital Object Identifier: 10.1188/14.CJON.465-467

A 64-year-old woman, A.L., was admitted to the oncology unit for neoadjuvant chemotherapy for a new diagnosis of breast cancer. On admission, the patient was alert and oriented. She was mildly obese and ambulated with a walker. She reported normal bowel and bladder function and described a “pain and stiffness” in her left leg.

Her past medical history included frequent falls at home, which she attributed to joint disease. Magnetic resonance imaging showed spinal stenosis and lumbar spine disease. Two months prior to the current hospitalization, A.L. had a breast biopsy for a right breast mass. Histopathology revealed invasive ductal carcinoma and ductal carcinoma in situ. Estrogen and progesterone receptors were positive, HER2-neu receptors were negative, and 2 of 10 axillary lymph nodes were positive, which confirmed stage III disease. Neoadjuvant treatment was ordered with four cycles of doxorubicin, cyclophosphamide, and docetaxel every 21 days. Because of limited mobility, A.L. received her treatments as an inpatient on the oncology unit.

After two cycles, A.L. reported increased pain and stiffness in her legs and back and spent most of her time in bed. She had lumbar spinal decompression surgery with little improvement in her symptoms. On her third cycle, she reported spasms in her knees when she flexed her ankles or inverted her toes. The spasms increased when she was anxious and with certain noises (e.g., IV pump beeping, doors opening and closing). She received opioid analgesics for pain and baclofen for leg spasms. Differential diagnoses included hyper-excitability neuromuscular disorders and dystonia, in addition to spinal degenerative arthritis.

After completing chemotherapy, A.L. went to a rehabilitation facility and was then readmitted to the hospital for a right breast mastectomy. After a brief stay on the postsurgical unit, she transferred to the oncology unit. Her neurologic state progressively declined, and she continually screamed in pain. Her leg spasms increased 10-fold with sudden noises even at low-volume intensities, and she developed contractures in both legs (see Figure 1). She was unable to

focus or hold a short conversation. She had to be prompted to swallow food and medications, and she lost 30 pounds. Serum and cerebrospinal fluid (CSF) anti-amphiphysin antibody testing was ordered; the results were positive. She was diagnosed with paraneoplastic stiff person syndrome (SPS).

## Stiff Person Syndrome

SPS is a rare paraneoplastic neurologic disorder characterized by underlying primary malignancy and progressive impairment of the central nervous system (CNS) (Greenlee, 2010). Paraneoplastic disorders are immune-mediated and are not related to metastatic disease, cancer treatment, or disease-related comorbidities such as infections or coagulopathies (Dalmau & Rosenfeld, 2013; Kanno, 2012). The syndrome is an antibody response to antigens on the surface of a cancerous tumor and is thought to be the body’s immune response to eliminating tumor cells (Byrne, Isakoff, Rincon, &

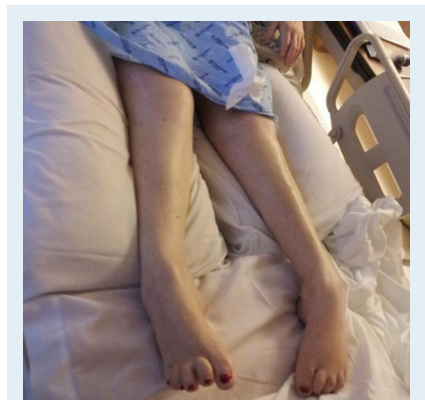


FIGURE 1. Bilateral Leg Contractures

Note. Photo used with permission.