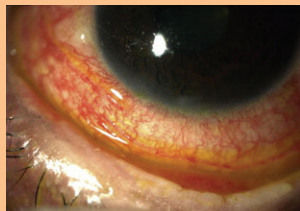


■ CNE Article

# Ocular Graft-Versus-Host Disease After Allogeneic Transplantation

Natasha L. Johnson, MS, ARNP, AOCNP®



Ocular graft-versus-host disease (GVHD) is a common complication that occurs after allogeneic transplantation. It can cause severe dry eyes that are described as having a burning, gritty, and painful sensation. Ocular GVHD can affect quality of life by causing pain and photophobia, limiting activities of daily living (e.g., reading, watching television), compromising safety while driving, and permanently damaging vision. Pre- and post-transplantation evaluations by an ophthalmologist are recommended. Routine assessments using the National Institutes of Health eye score should be administered to patients at each follow-up visit to their transplantation physician. Treatment options include lubricating eye drops, immunomodulator and steroid drops, and punctal occlusion. Relieving symptoms is difficult, and although multiple treatment options exist, many are ineffective. The Boston Foundation for Sight's scleral lens is an available option that promotes corneal healing and symptom relief. The current article discusses treatment options and supportive care measures for patients with ocular GVHD aimed at relieving symptoms and preventing complications.

Natasha L. Johnson, MS, ARNP, AOCNP®, was a case manager at Infinity Homecare in Lakeland, FL. The author takes full responsibility for the content of the article. The author did not receive honoraria for this work. The content of this article has been reviewed by independent peer reviewers to ensure that it is balanced, objective, and free from commercial bias. No financial relationships relevant to the content of this article have been disclosed by the author, planners, independent peer reviewers, or editorial staff. Johnson can be reached at [nlthorpe@msn.com](mailto:nlthorpe@msn.com), with copy to editor at [CJONEditor@ons.org](mailto:CJONEditor@ons.org). (Submitted December 2012. Revision submitted February 2013. Accepted for publication April 26, 2013.)

Digital Object Identifier: 10.1188/13.CJON.621-626

Photo reprinted from *Saudi Journal of Ophthalmology*, 27(3), by A. Nassar, K.F. Tabbara, & M. Aljurf, "Ocular Manifestations of Graft-Versus-Host Disease," p. 217, 2013, with permission from Elsevier.

**A** 30-year-old man named M.E. had chronic graft-versus-host disease (GVHD) in his eyes, skin, and gastrointestinal tract. He received a matched, unrelated allogeneic transplantation six years ago that included total body radiation. He did not receive prophylactic treatment for GVHD prior to transplantation and, within 30 days, he experienced acute GVHD symptoms that resolved within six months post-transplantation. Two years after the transplantation, M.E. began feeling burning and scratching symptoms in his eyes and experienced pain and difficulty keeping his eyes open. His physician treated him with lubricating eye drops, topical and oral steroids, and cyclosporine eye drops. He also was taking immunomodulators, including tacrolimus and mycophenolate mofetil, as systemic therapy for GVHD. Those treatment options did not improve his ocular manifestations. His physician referred him to an ophthalmologist who specialized in ocular GVHD. He was treated with punctal plugs one year after his ocular symptoms began, but they repeatedly fell out. As the symptoms worsened, his eyes often appeared very red and swollen. He had great difficulty driving to and from work because of the bright lights, burning sensations, and frequent need to administer lubricating eye drops. M.E. struggled daily with

the severity of his symptoms until his local optometrist suggested that he should go to the Boston Foundation for Sight to be evaluated for scleral lenses. Four years post-transplantation, M.E. was seen and fitted with the lenses, and he reported relief within 48 hours. He remained in Boston for two weeks to be trained to apply the scleral lenses. When he returned home, he was able to enjoy things that he had been unable to do or had suffered through for two years. Scleral lenses improved M.E.'s quality of life by relieving his photophobia and eye pain and improving overall functional status.

## Ocular Graft-Versus-Host Disease

Patients are surviving hematologic malignancies (e.g., leukemia, lymphoma, multiple myeloma) because of the increased use of hematopoietic stem cell transplantation (Fraser et al., 2006). Despite the advances in treatment, patients receiving allogeneic transplantations may experience major complications (e.g., GVHD) that can significantly affect quality of life and become life threatening. GVHD, the most common complication, occurs because the hematopoietic stem cells do not recognize the host's tissues and begin to attack like an exaggerated immune response (Choi, Levine, & Ferrara, 2010). In contrast to