

Superior Vena Cava Syndrome

Jo Ann Flounders, MSN, CRNP, APRN, BC, OCN®, CHPN

Goal for CE Enrollees:

To further enhance nurses' knowledge regarding superior vena cava syndrome (SVCS).

Objectives for CE Enrollees:

On completion of this CE, the participant will be able to

1. Describe the etiology of SVCS.
2. Discuss the clinical manifestations and medical management of patients with SVCS.
3. Discuss the nursing implications in the care of patients with SVCS.

Superior vena cava syndrome (SVCS) describes a clinical scenario that occurs when a mechanical obstruction occludes the superior vena cava. Obstruction may be the result of extraluminal compression by a tumor or enlarged lymph nodes or intraluminal obstruction by thrombosis or tumor (Smeltzer & Bare, 1996; Uaje, Kahsen, & Parish, 1996). The result of the compression or obstruction of the superior vena cava is blocked venous drainage that, in turn, causes pleural effusions and edema of the face, arm, and trachea. With severe superior vena cava obstruction, altered consciousness and focal neurologic signs caused by cerebral edema and impaired cardiac filling can occur (DeMichele & Glick, 2001).

Etiology

The most common cause of SVCS is malignant disease (Aurora, Milite, & Vander Els, 2000; DeMichele & Glick, 2001; Dietz & Flaherty, 1993; Schafer, 1997; Yahalom, 1993). The risk of developing SVCS for patients with cancer corresponds to the etiologic factors that cause SVCS. SVCS occurs most frequently in men aged 50–70 years who have primary or metastatic tumors of the mediastinum (Haapoja & Blendowski, 1999). Advanced lung cancer, specifically small cell carcinoma of the lung and, less frequently, non-small cell lung cancer (e.g., squamous cell carcinoma, adenocarcinoma), causes more than 75% of malignant superior vena cava obstructions. Higher risk of SVCS occurs with right-sided lung carcinomas because of anatomic proximity to the superior vena cava. Non-Hodgkin's lymphoma involving the

mediastinum, usually with right-sided perihilar lymphadenopathy, also is a cause of SVCS (Haapoja & Blendowski). However, Hodgkin's lymphoma rarely causes SVCS, although it does involve the mediastinum (Yahalom). Mediastinal metastases, which are more common in breast carcinoma, as well as Kaposi's sarcoma, thymoma, fibrous mesothelioma, and germ cell neoplasms commonly are associated with SVCS (Chen, Bongard, & Klein, 1990; Haapoja & Blendowski; Yahalom) (see Figure 1).

Nonmalignant causes of SVCS include granulomatous infections secondary to tuberculosis, goiter, aortic aneurysms, and histoplasmosis-related mediastinal fibrosis (Aurora et al., 2000; Haapoja & Blendowski, 1999; Yahalom, 1993). Iatrogenic causes of SVCS include venous thrombosis as a consequence of central venous catheters or pacemaker catheters and fibrosis caused by radiation therapy of the mediastinum (Yahalom).

Physiology

The superior vena cava is located in the mid-third of the right anterior superior mediastinum behind the sternum (Haapoja & Blendowski, 1999; Smeltzer & Bare, 1996). The venous drainage from the head, neck, upper extremities, and upper thorax collects in the superior vena cava en route to the right atrium (Haapoja & Blendowski). A number of veins drain into the superior vena cava (Martini, 1998) (see Figure 2).

1. The cephalic vein joins the axillary vein, exits the arm, and forms the subclavian vein at the level of the lateral surface of the first rib.
2. The subclavian vein, which is located superior to the first rib and along the superior margin of the clavicle, meets the internal and external jugular veins of the same side of the body.
3. This fusion creates the brachiocephalic or innominate vein, which receives blood from the vertebral vein of the skull and spinal cord and from the internal thoracic vein.
4. The brachiocephalic veins from each side of the body join at the level of the first and second ribs to create the superior vena cava, which terminates in the right atrium.

Jo Ann Flounders, MSN, CRNP, APRN, BC, OCN®, CHPN, is a nurse practitioner at Consultants in Medical Oncology and Hematology in Drexel Hill, PA.

Digital Object Identifier: 10.1188/03.ONF.E84-E90

1. Patients with small cell lung cancer or, less frequently, non-small cell lung carcinoma (e.g., squamous cell carcinoma) and those with right lung involvement
2. Patients with non-Hodgkin's lymphoma
3. Male patients aged 50–70 years who have primary or metastatic tumors of the mediastinum
4. Patients with breast carcinoma and mediastinal metastasis, Kaposi's sarcoma with mediastinal involvement, thymoma, fibrous mesothelioma, and germ cell neoplasms
5. Patients with central venous catheters and pacemaker catheters
6. Patients who have received previous radiation therapy to the mediastinum
7. Patients with cancer who have comorbid conditions such as tuberculosis, histoplasmosis, or aortic aneurysm

Figure 1. Patients With Cancer at Increased Risk for Superior Vena Cava Syndrome

SVCS is a result of impaired venous drainage when the superior vena cava is compressed extra- or intraluminally, causing venous hypertension and congestion of the veins draining into the superior vena cava from the head, neck, upper extremities, and upper thorax (Dietz & Flaherty, 1993; Haapoja & Blendowski, 1999; Schafer, 1997). Several factors cause the vulnerability of the superior vena cava to compression. The superior vena cava is located inside the rigid walls of the thoracic cavity along with the heart, lungs, esophagus, trachea, aorta, pulmonary artery, and lymph nodes. The superior vena cava is surrounded by inflexible structures, such as the sternum, ribs, vertebral bodies, and aorta, with its high intravascular pressure. The right main bronchus is located very close to the superior vena cava. Because the superior vena cava is a thin-walled blood vessel with low intravascular pressure enclosed in a tight compartment, it can be compressed easily because the chest has no room for expansion (Dietz & Flaherty).

Extraluminal compression of the superior vena cava by tumors or enlarged lymph nodes can occur acutely or gradually. Obstruction can be complete or partial, and collateral venous drainage may develop. Intraluminal obstruction of the superior vena cava can be caused by infiltration by tumor, although thrombosis is the more common cause. Acute and complete obstruction of the superior vena cava is caused more often by thrombosis than by compression or infiltration by tumor (Baker & Barnes, 1992; Haapoja & Blendowski, 1999). Risk factors for the formation of thrombus in the superior vena cava include a hypercoagulable state in patients with malignancy,

damage to the intima of the superior vena cava from central venous catheters, and venous stasis from extraluminal compression (Haapoja & Blendowski).

The development of SVCS is dependent on several factors, including the growth rate of the tumor, extent and location of the blockage, patency of the azygos vein, and ability to develop collateral circulation (Schafer, 1997). Collateral circulation bypasses the site of obstruction and redirects blood flow from the upper thoracic venous system and the obstructed superior vena cava to the inferior vena cava en route to the right atrium. Blood flow is redirected to the azygos vein, internal mammary veins, thoracic venous system, and vertebral veins (Haapoja & Blendowski, 1999). Subcutaneous veins also are important alternative pathways that improve circulation when the superior vena cava is fully or partially obstructed (Yahalom, 1993).

The most important alternative pathway is the azygos venous system (Yahalom, 1993). The azygos vein is a major tributary of the superior vena cava and joins it at the level of the second thoracic vertebra (Martini, 1998). Impaired venous drainage above the level of the azygos vein causes less venous pressure and less pronounced SVCS because the venous return from the upper body can be redirected from the subclavian vein to the azygos vein, proximal vena cava, and right atrium (Haapoja & Blendowski, 1999; Schafer, 1997). Impaired venous drainage below the azygos vein is a more complex problem and causes more symptoms because the shunted blood must return to the right atrium by way of the upper abdominal veins and the inferior vena cava, which requires higher venous pressure. When venous circulation through the superior vena cava is impaired, venous hypertension, venous stasis, and decreased cardiac output result. If untreated, these will progress to thrombosis, laryngeal and cerebral edema, stupor, coma, pulmonary complications, and death (Schafer).

Clinical Manifestations

Symptoms

The development of clinical manifestations of SVCS depends on the amount of venous hypertension, the delay in circulation time, the development of collateral pathways of circulation, and the clinical signs and symptoms of the underlying causative pathophysiologic process (Baker & Barnes, 1992; Uaje et al., 1996). Also important is the degree and rapidity of obstruction of the superior vena cava (Haapoja & Blendowski, 1999; Schafer, 1997; Yahalom, 1993). If onset of SVCS is gradual, symptoms may be subtle (e.g., facial, neck, or arm swelling upon arising in the morning because of venous engorgement). Patients may have difficulty removing rings from fingers. Patients often notice increased symptoms in the morning after sleeping in a supine position or with position changes such as bending forward or stooping. Rapid onset of SVCS, in the absence of collateral circulation, will cause a more dramatic and life-threatening presentation, often with neurologic and respiratory sequelae resulting from cerebral and laryngeal edema.

In addition to swelling of the face, arms, fingers, or neck, patients may notice the following early symptoms of SVCS (Haapoja & Blendowski, 1999; Hunter, 1998; Yahalom, 1993).

- Dyspnea, which is the most common symptom, and nonproductive cough

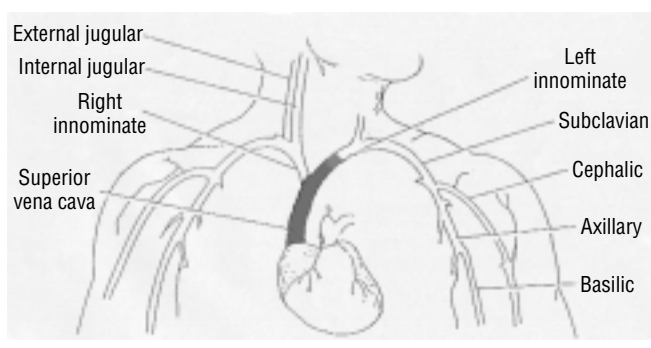


Figure 2. Venous Circulation Including the Superior Vena Cava

- Feeling of fullness of the head
- Difficulty buttoning shirt collars (Stoke's sign); women also may experience breast swelling
- Dysphagia and hoarseness
- Chest pain

Late symptoms of SVCS include

- Life-threatening symptoms of respiratory distress, such as orthopnea
- Headache, visual disturbances, dizziness, and syncope
- Lethargy, irritability, and mental status changes.

Physical Examination

After consideration of risk factors and a review of symptoms indicative of SVCS, a physical examination must be completed. Early physical signs of SVCS include (Haapoja & Blendowski, 1999; Hunter, 1998; Yahalom, 1993)

- Edema of the face, neck, upper thorax, breasts, and upper extremities
- Prominent venous pattern (i.e., dilated veins of face, neck, and thorax)
- Jugular vein distention
- Periorbital edema and redness and edema of conjunctivae
- Facial plethora (ruddy complexion of face or cheeks)
- Compensatory tachycardia.

Late signs of SVCS include

- Cyanosis of the face or upper torso
- Engorged conjunctivae
- Mental status changes
- Tachypnea, orthopnea, stridor, and respiratory distress
- Stupor, coma, seizures, and death.

Diagnostic Studies

Accurate, definitive histologic diagnosis is necessary to provide appropriate treatment of SVCS because the modality of treatment usually is based on the histologic diagnosis of the underlying malignancy (Yahalom, 1993). However, the choice of diagnostic procedures with suspected SVCS depends on patients' status. On rare occasions, patients will present with life-threatening clinical manifestations of SVCS that warrant immediate treatment (Baker & Barnes, 1992; DeMichele & Glick, 2001; Dietz & Flaherty, 1993). Emergency treatment without histologic diagnosis is reserved for patients who demonstrate brain edema with mental status changes, decreased cardiac output with hemodynamic compromise, or laryngeal edema with respiratory compromise and impending loss of airway (DeMichele & Glick). Therefore, if the development of SVCS is rapid with acute respiratory and neurologic symptoms, treatment (e.g., radiation therapy) may be started immediately before a definitive tissue diagnosis is obtained. Tissue diagnosis and a complete workup for metastasis then can proceed during treatment (Schafer, 1997). However, if the development of SVCS is gradual, as occurs more commonly, the diagnostic workup should be completed first to confirm a definitive diagnosis before treatment is initiated. Appropriate workup for epidural extension of malignant disease (magnetic resonance imaging [MRI] of the spine) or pericardial involvement (echocardiogram) should be completed as necessary.

The preferred diagnostic tools to confirm the diagnosis of SVCS are chest computed tomography (CT) scan with IV contrast and chest MRI scan (Chen et al., 1990; DeMichele & Glick, 2001; Haapoja & Blendowski, 1999). CT and MRI

scans are noninvasive, accurate in distinguishing between tumor mass or thrombosis as causes of SVCS, and able to document the extent and the location of involvement. Chest x-ray films also may be obtained. Chest x-ray results that are associated with SVCS include a lung or mediastinal mass, pleural effusion, and superior mediastinal widening (Hunter, 1998; Yahalom, 1993). In SVCS, lung masses frequently are seen on the right on chest x-ray films because the superior vena cava enters from the right (Schafer, 1997).

The least invasive technique should be used to obtain a biopsy or cytology specimen if necessary to confirm histologic diagnosis of the underlying malignancy. Collection of sputum for cytology is useful when bronchogenic carcinoma is suspected. Biopsy of a palpable lymph node is a useful, low-risk diagnostic test (Schafer, 1997). Bronchoscopy with brushings, mediastinoscopy, or biopsy of a supraclavicular node can provide specimens for accurate tissue diagnosis (DeMichele & Glick, 2001; Haapoja & Blendowski, 1999; Yahalom, 1993). However, a risk of bleeding exists with these invasive procedures because of the increased venous pressure in the head and neck. A thoracentesis should be performed if increased pleural fluid is present (Aurora et al., 2000). Bone marrow biopsy may be useful when small cell carcinoma of the lung or non-Hodgkin's lymphoma is suspected because these malignancies often involve the bone marrow. A bone marrow biopsy may reduce the need for a pulmonary procedure at a time when bleeding is a possible risk factor (Yahalom).

Medical Management

The four main treatment modalities for SVCS are radiation therapy, chemotherapy, pharmacologic therapy, and surgery. In patients with cancer, treatment depends on the causative factors of SVCS, severity of the symptoms, underlying malignancy, patient's prognosis, and presence of thrombosis (Haapoja & Blendowski, 1999). Treatment is based on the histologic diagnosis of the primary tumor (Hunter, 1998), the rate of onset, and the type of obstruction, either intra- or extraluminal (Schafer, 1997). Goals of treatment include relief of the obstruction and symptoms. The goal of treatment is cure when the primary disease is small cell lung cancer, non-Hodgkin's lymphoma, or a germ cell tumor.

Radiation therapy is the primary treatment modality for patients with SVCS caused by non-small cell lung cancer and has been advocated for most patients with SVCS caused by any malignancy (Haapoja & Blendowski, 1999; Hunter, 1998; Knopp, 1997; Schafer, 1997; Yahalom, 1993). Emergency radiotherapy treatment is started immediately without histologic diagnosis only when patients present with acute, life-threatening symptoms (Schafer). In most situations, however, a tissue or cytologic diagnosis should be made before radiation treatment is started (Knopp). The treatment field should include the tumor with appropriate margins and the mediastinal and hilar lymph nodes (DeMichele & Glick, 2001; Knopp; Yahalom). Patients with non-small cell lung cancer with mediastinal adenopathy and without distant metastases usually have the supraclavicular nodes included in the radiation treatment field.

Daily radiotherapy doses for patients with SVCS are usually 300–400 cGy for the first two to four days in hopes of obtaining expedient symptom relief, followed by daily dose fractions of 180–200 cGy (Knopp, 1997; Schafer, 1997;

Yahalom, 1993). The total dose of radiation is determined by the histologic diagnosis and the extent of disease (Knopp). Many patients demonstrate clinical improvement before objective signs of tumor reduction are noted on chest x-rays (DeMichele & Glick, 2001). Symptom relief occurs within three weeks in 85%–90% of patients (Knopp), and many notice improvement in symptoms within three to four days of initiating radiotherapy (Haapoja & Blendowski, 1999). Symptomatic improvement is a result of the improved flow of blood through the superior vena cava, as well as the development of collateral pathways of venous blood flow after the increased pressure in the mediastinum is relieved (Ahmann, 1984; Yahalom).

The side effects of radiation therapy are related to the tissues included in the radiation field, the length and dose of radiotherapy, and the status of the patient (Sitton, 1998). Potential side effects include skin changes, fatigue, dyspnea, cough, pneumonitis, anorexia, pharyngitis, esophagitis, leukopenia, and anemia (Haapoja & Blendowski, 1999; Knopp, 1997; Sitton).

Chemotherapy provides local and systemic treatment of neoplastic disease and is used to treat highly chemosensitive malignancies such as small cell lung cancer and lymphoma (Haapoja & Blendowski, 1999; Schafer, 1997; Yahalom, 1993). Chemotherapy is the treatment of choice for patients who previously have received the maximum dose of mediastinal radiation therapy (Dietz & Flaherty, 1993; Hunter, 1998).

Treatment for small cell lung cancer includes platinum-based chemotherapy regimens such as cisplatin or carboplatin with etoposide. Cyclophosphamide-based regimens, such as cyclophosphamide, doxorubicin, and vincristine, also may be used (Haapoja & Blendowski, 1999; Thomas, Williams, Cobos, & Turrisi, 2001). Chemotherapeutic treatment for non-Hodgkin's lymphoma is based on the stage and histologic type of lymphoma. Possible chemotherapies include single-agent drugs, such as cyclophosphamide or fludarabine, as well as combinations of drugs such as cyclophosphamide, doxorubicin, vincristine, and prednisone (Cheson, 2001). Relief of symptoms of SVCS often occurs within 7–14 days in most patients with malignancy-induced SVCS treated with chemotherapy (Haapoja & Blendowski; Yahalom, 1993). Multimodality therapy with chemotherapy in combination with radiation therapy may be used.

Pharmacologic treatment of SVCS includes steroids, diuretics, and thrombolytic therapy (Hunter, 1998). Medical management of SVCS with corticosteroids and diuretics alone may be used when patients demonstrate minimal symptoms and have adequate collateral venous blood flow (Aurora et al., 2000; Haapoja & Blendowski, 1999). The goal of treatment with diuretics and corticosteroids is reduction in edema and inflammation; however, the benefit of the use of corticosteroids and diuretics is controversial (Escalante, 1993; Haapoja & Blendowski; Yahalom, 1993). A potential side effect of diuretic therapy is hypovolemic shock caused by decreased vascular volume with diuresis and the resultant low venous return to the heart (Schafer, 1997).

Thrombolytic therapy may be used when SVCS is caused by catheter-induced intraluminal thrombosis. Thrombolytic therapy or tissue plasminogen activators are used to treat catheter-induced thrombosis and can effectively lyse clots (Greenberg, Kosinski, & Daniels, 1991; Haapoja & Blendowski, 1999; Ingle, 1997). Treatment with thrombolytics

should be initiated within five to seven days of the onset of symptoms for maximum effectiveness (Aurora et al., 2000; Stewart, 1996). Catheter removal may be necessary.

Anticoagulants may be used to help relieve venous obstruction by preventing thrombus formation when SVCS is caused by a tumor. However, pharmacologic management of SVCS with anticoagulant therapy is controversial (DeMichele & Glick, 2001; Nomori, Nara, Morinaga, & Soejima, 1998). The risk of hemorrhage with anticoagulant therapy must be weighed against the possible benefits. One potential preventive measure for catheter-induced thrombosis is prophylactic administration of 1 mg per day of warfarin (Bern et al., 1990; Haapoja & Blendowski, 1999).

Surgical intervention for SVCS includes stent placement or superior vena cava bypass and is used occasionally when SVCS is chronic or recurrent (Ingle, 1997; Schafer, 1997). Surgical intervention in patients with malignancy-induced SVCS should be reserved for patients who have failed other therapeutic treatments such as radiation therapy and chemotherapy. Surgery to relieve the obstruction may be beneficial in patients with retrosternal goiter or aortic aneurysm (Yahalom, 1993).

Nursing Care

Recognition of early signs of SVCS can allow treatment before life-threatening symptoms of respiratory and neurologic distress occur. Early detection of SVCS will allow time for accurate histologic diagnosis in patients with an undiagnosed malignancy or an unknown etiology of SVCS. Accurate diagnosis is necessary so that prompt and successful treatment of the underlying causative malignancy may be initiated. Nurses frequently are able to perceive subtle changes in the status of patients and should complete accurate and thorough ongoing assessment of cardiopulmonary status to identify early abnormal changes. For example, the inability to button shirts or complete activities of daily living because of dyspnea can be important early changes in patient status. In fact, nurses should assume a proactive role and ask patients who are at risk for SVCS if they are experiencing any of these symptoms. Nursing assessment includes strict monitoring of vital signs, level of consciousness, edema, tissue perfusion, respiratory status, functional status, and level of endurance of physical activity. Fluid and electrolyte balance should be monitored because overhydration may exacerbate the symptoms of SVCS (Haapoja & Blendowski, 1999; Uaje et al., 1996). In addition, diuretics may be used to decrease edema, necessitating attention to fluid and electrolyte balance.

Nursing interventions in patients with SVCS include measures to relieve dyspnea, such as elevating the head of the bed and providing oxygen (Haapoja & Blendowski, 1999; Hunter, 1998). Maintenance of IV access is challenging because venipunctures and IV fluid administration should be avoided in the upper extremities. Therefore, central venous access devices are necessary and require expert nursing management. Nurses should ensure that blood pressure measurement is avoided in the upper extremities. Assessment of patients for side effects of SVCS treatment is a primary nursing responsibility so that prompt intervention can be initiated. Potential side effects of radiation therapy include skin changes (e.g., erythema, dry or moist desquamation), fatigue, dyspnea, pneumonitis, dysphagia, pharyngitis, esophagitis, leukopenia,

and anemia. Potential side effects of chemotherapy include stomatitis, nausea, vomiting, fatigue, leukopenia, anemia, and thrombocytopenia. Therefore, nursing care of patients with SVCS undergoing radiation therapy and chemotherapy includes monitoring blood counts to detect bone marrow suppression (Haapoja & Blendowski). Nurses should provide instructions to the patient and family regarding self-care measures to prevent complications, such as notifying a physician when the patient's temperature is greater than 100.5°F or providing saline mouth rinses several times a day. If patients are treated with anticoagulant therapy, bleeding precautions should be emphasized with patients and caregivers. Nurses should assess for side effects of corticosteroids, such as weakness of involuntary muscles, mood swings, dyspepsia, insomnia, or hyperglycemia (Hunter). Postoperative assess-

ment and interventions to prevent complications are necessary for patients who have been treated with surgical intervention. Nurses should assess patients and caregivers for ineffective coping, depression, and anxiety and provide interventions to improve coping abilities. Assessment of pain and interventions to relieve pain should be ongoing. Discharge planning should include consideration of referral for homecare or hospice services as needed.

The author would like to thank John Sprandio, MD, of Consultants in Medical Oncology and Hematology in Drexel Hill, PA, for reviewing this manuscript.

Author Contact: Jo Ann Flounders, MSN, CRNP, APRN, BC, OCN®, CHPN, can be reached at joann@theflounders.com, with copy to editor at rose_mary@earthlink.net.

References

- Ahmann, F. (1984). A reassessment of the clinical applications of the superior vena cava syndrome. *Journal of Clinical Oncology*, 2, 961–969.
- Aurora, R., Milite, F., & Vander Els, N. (2000). Respiratory emergencies. *Seminars in Oncology*, 27, 256–269.
- Baker, G. & Barnes, H. (1992). Superior vena cava syndrome: Etiology, diagnosis, and treatment. *American Journal of Critical Care*, 1, 54–64.
- Bern, M., Lokich, J., Wallach, S., Bothe, A., Benotti, P., Arkin, C., et al. (1990). Very low dose of warfarin can prevent thrombosis in central venous catheters. *Annals of Internal Medicine*, 112, 423–428.
- Chen, J., Bongard, F., & Klein, S. (1990). A contemporary perspective on superior vena cava syndrome. *American Journal of Surgery*, 160, 207–211.
- Cheson, B. (2001). Hodgkin's disease and the non-Hodgkin's lymphomas. In R. Lenhard, R. Osteen, & T. Gansler (Eds.), *Clinical oncology* (pp. 497–516). Atlanta, GA: American Cancer Society.
- DeMichele, A., & Glick, J. (2001). Cancer-related emergencies. In R. Lenhard, R. Osteen, & T. Gansler (Eds.), *Clinical oncology* (pp. 733–764). Atlanta, GA: American Cancer Society.
- Dietz, K., & Flaherty, A. (1993). Oncologic emergencies. In S. Groenwald, M. Frogge, M. Goodman, & C. Yarbrow (Eds.), *Cancer nursing principles and practice* (3rd ed., pp. 800–839). Boston: Jones and Bartlett.
- Escalante, C. (1993). Causes and management of superior vena cava syndrome. *Oncology*, 7(6), 61–68.
- Greenberg, S., Kosinski, R., & Daniels, J. (1991). Treatment of superior vena cava thrombosis with recombinant tissue type plasminogen activator. *Chest*, 99, 1298–1301.
- Haapoja, I., & Blendowski, C. (1999). Superior vena cava syndrome. *Seminars in Oncology Nursing*, 15, 183–189.
- Hunter, J. (1998). Structural emergencies. In J. Itano & K. Taoka (Eds.), *Core curriculum for oncology nursing* (3rd ed., pp. 340–354). Philadelphia: Saunders.
- Ingle, R. (1997). Lung cancers. In S. Groenwald, M. Frogge, M. Goodman, & C. Yarbrow (Eds.), *Cancer nursing principles and practice* (4th ed., pp. 1260–1290). Boston: Jones and Bartlett.
- Knopp, J. (1997). Lung cancer. In K. Dow, J. Bucholtz, R. Iwamoto, V. Fieler, & L. Hilderley (Eds.), *Nursing care in radiation oncology* (2nd ed., pp. 293–315). Philadelphia: Saunders.
- Martini, F. (1998). *Fundamentals of anatomy and physiology* (4th ed.). Upper Saddle River, NJ: Prentice Hall.
- Nomori, H., Nara, S., Morinaga, S., & Soejima, K. (1998). Primary malignant lymphoma of superior vena cava. *Annals of Thoracic Surgery*, 66, 1423–1424.
- Schafer, S. (1997). Oncologic complications. In S. Otto (Ed.), *Oncology nursing* (3rd ed., pp. 406–474). St. Louis, MO: Mosby Yearbook.
- Sitton, E. (1998). Nursing implications of radiation therapy. In J. Itano & K. Taoka (Eds.), *Core curriculum for oncology nursing* (3rd ed., pp. 616–629). Philadelphia: Saunders.
- Smeltzer, S., & Bare, B. (1996). Oncology: Nursing the patient with cancer. In S. Smeltzer & B. Bare (Eds.), *Brunner and Suddarth's textbook of medical-surgical nursing* (8th ed., pp. 309–316). Philadelphia: Lippincott-Raven.
- Stewart, I. (1996). Superior vena cava syndrome: An oncologic complication. *Seminars in Oncology Nursing*, 12, 312–317.
- Thomas, C., Williams, T., Cobos, E., & Turrisi, A. (2001). Lung cancer. In R. Lenhard, R. Osteen, & T. Gansler (Eds.), *Clinical oncology* (pp. 269–295). Atlanta, GA: American Cancer Society.
- Uaje, C., Kahsen, K., & Parish, L. (1996). Oncology emergencies. *Critical Care Nursing Quarterly*, 18(4), 26–34.
- Yahalom, J. (1993). Oncologic emergencies. In V. DeVita, S. Hellman, & S. Rosenberg (Eds.), *Cancer: Principles and practice of oncology* (4th ed., pp. 2370–2385). Philadelphia: Lippincott-Raven.

For more information . . .

- eMedicine: Superior Vena Cava Syndrome
www.emedicine.com/EMERG/topic561.htm
- National Cancer Institute: Superior Vena Cava Syndrome
www.nci.nih.gov/cancerinfo/pdq/supportivecare/superior-vena-cava/healthprofessional

Links can be found using ONS Online at www.ons.org.