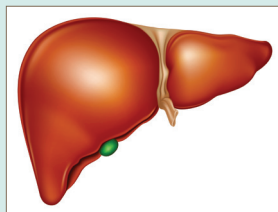


■ CNE Article

Veno-Occlusive Disease in Hematopoietic Stem Cell Transplantation Recipients

Elisabeth C. Sosa, RN, MSN, OCN®



© iStockphoto.com/Anna Sumska

Veno-occlusive disease (VOD) is a potentially fatal complication of hematopoietic stem cell transplantation that affects the liver, as well as other organs. Although mild cases resolve on their own, severe cases of VOD carry a high mortality rate. The diagnosis usually is clinically based, with nonspecific signs such as weight gain, ascites, hepatomegaly, right upper quadrant abdominal pain, and elevated serum bilirubin. Although studies are ongoing, no U.S. Food and Drug Administration–approved treatments for VOD exist to date. Therefore, supportive care is a critical part of the treatment plan. Oncology nurses should be familiar with the risk factors and clinical signs of VOD so that patients can be monitored closely for its occurrence. Accurate and timely recognition of VOD is crucial for appropriate treatment.

Elisabeth C. Sosa, RN, MSN, OCN®, is a staff nurse at Florida Hospital in Orlando. The author takes full responsibility for the content of the article. The author did not receive honoraria for this work. The content of this article has been reviewed by independent peer reviewers to ensure that it is balanced, objective, and free from commercial bias. No financial relationships relevant to the content of this article have been disclosed by the author, planners, independent peer reviewers, or editorial staff. Sosa can be reached at elisabeth.c.sosa@gmail.com, with copy to editor at CJONEditor@ons.org. (First submission November 2011. Revision submitted February 2012. Accepted for publication March 4, 2012.)

Digital Object Identifier:10.1188/12.CJON.507-513

Each year, about 20,000 hematopoietic stem cell transplantations are performed in the United States to treat a variety of malignant and nonmalignant diseases (Pasquini & Wang, 2011). About 12,000 transplantations are autologous, in which patients receive their own stem cells after a course of myeloablative therapy. The remaining 8,000 transplantations are allogeneic, in which patients receive stem cells, bone marrow, or cord blood from a matched related or unrelated donor (Pasquini & Wang, 2011).

Numerous complications can arise as a result of transplantation, including infections, renal failure, and complications of the liver, such as veno-occlusive disease (VOD) (Anderson-Reitz, 2011; Wujcik, Ballard, & Camp-Sorrell, 1994). VOD is the most common hepatic complication in the immediate post-transplantation period. Infections, graft-versus-host disease, and VOD are the most common causes of death after transplantation (Jones et al., 1987; McDonald, Sharma, Matthews, Shulman, & Thomas, 1984).

The incidence of VOD ranges from 0%–70% (Carreras et al., 1998). The large range may be attributed to the population studied, type of transplantation (autologous versus allogeneic), type of chemotherapy or radiation used, and how VOD was defined. The mortality rate ranges from 18%–50% and varies depending on the severity of VOD. Severe VOD has mortality rates from 66%–98% (Bearman, 1995; Bearman et

al., 1990; Carreras et al., 1998; Jones et al., 1987; McDonald et al., 1984, 1993).

Current nursing literature about VOD is lacking. Eisenberg (2008) discussed VOD, and Saria and Gosselin-Acomb (2007) briefly addressed VOD in a nursing article about critical care issues in transplantation recipients. The purpose of this article is to describe VOD and discuss its causes, risk factors, preventive interventions, and treatment options. By having a clear understanding of VOD, nurses can recognize patients in the early stages and provide prompt treatment for this potentially fatal complication. In addition, this article will bring to light new developments concerning risk factors, prevention, and treatment.

Pathophysiology

VOD is a complication of transplantation that affects the liver. The functional unit of the liver is the lobule, which is hexagonal and focused around a terminal hepatic vein (see Figure 1). The liver contains about 50,000–100,000 lobules. Blood flows from the portal vein and hepatic artery into the lobule. Blood then is directed to the exchange area of the lobule, known as the sinusoids. The walls of the sinusoids are lined with Kupffer cells, which eliminate foreign substances from the blood. The sinusoids also are lined with delicate sinusoidal endothelial cells. From the sinusoids, blood then returns to the vena cava (Eisenberg, 2008; Grandt, 1989; Robinson, 2005).