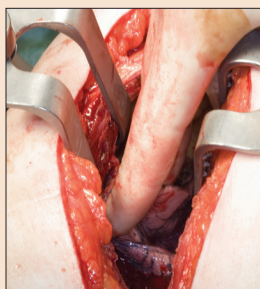


■ CNE Article

Post-Thoracotomy Pain Syndrome: Assessment and Intervention

Kathleen Garrubba Hopkins, MS, RN, and Margaret Rosenzweig, PhD, APN-BC, AOCNP®



© Dr. P. Marazzi/Photo Researchers, Inc.

Surgery is a cornerstone of treatment in early-stage non-small cell lung cancer. Chronic postoperative thoracotomy pain, post-thoracotomy pain syndrome (PTPS), is a condition occurring in 50% of postsurgical patients with lung cancer and is largely unrecognized. This article examines the diagnosis and treatment of PTPS to assist oncology nurses in providing better care to this patient population. Post-thoracotomy pain in patients with lung cancer may be under-reported and undertreated. Causes from the thoracotomy can be trauma and compression to the intercostal nerves, fractured and compressed ribs, inflammation of the chest muscles, atrophy of chest muscles, or scar tissue rubbing. This article examines the diagnosis and treatment of PTPS to assist oncology nurses in providing better care to this patient population. If left untreated, chronic pain can have a deleterious effect on patients' recovery and overall well-being. Oncology nurses should be aware of the signs and symptoms of PTPS so that more patients are diagnosed and choose to seek treatment.

Kathleen Garrubba Hopkins, MS, RN, is a doctoral student and Margaret Rosenzweig, PhD, APN-BC, AOCNP®, is an associate professor in Acute and Tertiary Care, both in the Department of Nursing at the University of Pittsburgh in Pennsylvania. The authors take full responsibility for the content of the article. The authors did not receive honoraria for this work. The content of this article has been reviewed by independent peer reviewers to ensure that it is balanced, objective, and free from commercial bias. No financial relationships relevant to the content of this article have been disclosed by the authors, planners, independent peer reviewers, or editorial staff. Hopkins can be reached at kgh6@pitt.edu, with copy to editor at CJONEditor@ons.org. (First submission September 2011. Revision submitted December 2011. Accepted for publication December 11, 2011.)

Digital Object Identifier:10.1188/12.CJON.365-370

The American Cancer Society (2012) reported 160,340 estimated deaths from lung and bronchus cancer, more than breast, colon, ovarian, and prostate cancers combined. In an attempt to surgically remove a lung tumor, many patients will undergo one of the following types of thoracotomy: traditional posterolateral, thoracoscopic, and posterolateral muscle-sparing.

In a traditional posterolateral thoracotomy, the patient typically is placed in the lateral position on the nonaffected side and the arm of the affected side is positioned anteriorly away from the incision site. An incision is made through the chest wall to remove the affected portion of lung. The incision typically passes through the major chest muscles, fourth and fifth rib intercostal spaces, and pleural and appropriate lobe where the surgeon removes the diseased portions of the affected lobe of the lung. Often during this procedure, to gain access to the thoracic cavity, the ribs are spread apart (Landreneau et al., 1994), which may cause damage to the ribs, intercostal nerves, and nerve bundles (Wildgaard, Ravn, & Kehlet, 2009). The procedure frequently results in damage to the latissimus dorsi muscle and less frequently to the serratus anterior muscle

(Benedetti et al., 1998; Landreneau et al., 1994; Perttunen, Tasmuth, & Kalsol, 1999).

Thoracoscopic surgery also is called video-assisted surgery or robotic surgery, which includes three to five two-inch incisions where endosurgical instrumentation passes through the major chest muscles, intercostal spaces of the ribs, and pleural cavity. Endosurgical instrumentation includes a series of thoroscopes, as well as several flexible or curved instruments with various holding and cutting ends specifically designed to remove the appropriate portions of the affected lobe of the lung. Even with this less invasive technique, the removal of the tumor can damage the ribs and nerves. However, once healed, the only visual reminders are the three to five two-inch scars (Landreneau et al., 1994; Perttunen et al., 1999; Wildgaard et al., 2009).

Another technique, posterolateral thoracotomy, is called muscle-sparing thoracotomy because access to the pleural cavity is obtained by entering through the fifth or sixth intercostal space, where obstruction of the major chest muscles is minimal. That approach results in a 6–10 inch scar on the lateral side, external to the larger fifth and sixth intercostal space region (see Figure 1).