

# Lymphedema in Breast Cancer: Dilemmas and Challenges

Marybeth Singer, MS, APN-BC, AOCN®, ACHPN

## Case Study

D.S. is a 40-year-old woman who completed all treatment for stage III breast cancer six months ago. At the time of diagnosis, a 3 cm mass was found in the upper outer quadrant of her left breast, and she had four positive lymph nodes at the time of definitive surgical treatment. She was treated with partial mastectomy and axillary node dissection followed by adjuvant chemotherapy. She did not need a ventricular assist device. Radiation therapy directed to her whole breast and axilla followed completion of chemotherapy. D.S. is married and works part-time as a computer programmer. Her children are ages 4 and 8. Now she presents for an acute care appointment after noting pain in her upper arm for several days followed one week later by swelling in her left hand. Prior to the onset of symptoms, D.S. had been very active with her daughter's birthday party held outdoors in August during hot, humid weather.

## Nursing Assessment

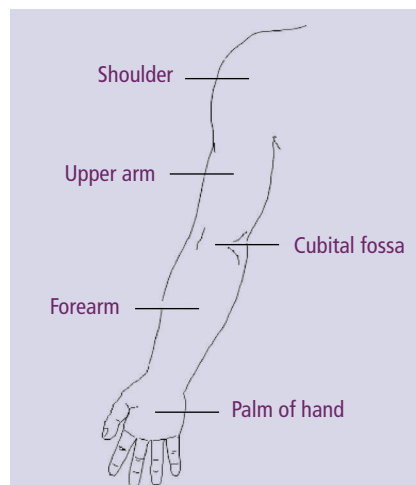
During the clinic visit, the nurse practitioner examines D.S.'s left arm visually and by palpation. The nurse notes that no evidence of erythema or of trauma to the skin or nails is present. Pitting edema is present in the left hand and soft fullness in the forearm and upper arm. Examination of the left breast reveals mild breast edema without significant erythema, and hyperpigmentation and tanning is observed after radiation. D.S. also is noted to have fullness in the left axilla without discrete adenopathy. Examination of her right breast and vital signs reveal normal findings. D.S. reports that her left arm

feels heavy and aches when she does household tasks. Today's visit focuses on assessing D.S. for lymphedema risk factors (i.e., any trauma, injury, or infection), evaluating for deep vein thrombosis or disease recurrence, preventing further compromise, and beginning effective treatment.

The nurse practitioner refers D.S. to the physical therapy department, where her left arm is measured with a tape measure at several points to assess size differences in comparison with her right arm (see Figure 1). A perometer also is used to measure D.S.'s arm volume. A perometer is an infrared optoelectronic device that scans the length of both arms to provide an accurate outline of limbs and allows for calculated volume difference (Armer & Stewart, 2005; Poage, Singer, Armer, Poundall, & Shellabarger, 2008). It is a frequently used measurement tool in lymphedema management and is a quick, accurate, and hygienic option for measurement. At this visit, D.S.'s left arm volume is revealed to be 9% greater than the right arm.

## Etiology of the Problem

Lymphedema of an extremity is a chronic condition that requires lifelong attention and management. It results from impairment or blockage of the flow of lymph fluid through lymphatic vessels or lymph nodes; most often it develops secondary to surgery or radiation used in cancer treatment. Injury to the lymphatics results in mechanical insufficiency that diminishes the normal ability of the



- Use a flexible, nonstretch metric tape to measure at the following intervals along the arm: hand proximal to metacarpal-phalangeal joint, wrist, and every 4 cm from wrist to axilla.
- Measure the affected and unaffected limbs for comparison.
- Difference of 2 cm or more from baseline (pretreatment) or between limbs is a commonly accepted criterion for lymphedema and should lead to further assessment by a lymphedema specialist.
- Baseline measures establish symmetry or asymmetry between limbs; contralateral measures also allow adjustment for body mass index changes.

## Figure 1. Circumferential Measurements of the Arm

*Note.* Based on information from Armer & Stewart, 2005. Diagram from "Arm (Diagram)," by Patient UK, 2009. Retrieved May 7, 2009, from <http://www.patient.co.uk/showdoc/21692483>. Copyright 2009 EMIS and PiP. Reprinted with permission.

Marybeth Singer, MS, APN-BC, AOCN®, ACHPN, is an oncology nurse practitioner in the Gillette Center for Breast Oncology at the Massachusetts General Hospital Cancer Center in Boston.

Digital Object Identifier: 10.1188/09.CJON.350-352