

## Polyneuropathy, Organomegaly, Endocrinopathy, Monoclonal Gammopathy, and Skin Changes (POEMS) Syndrome

Ellen C. Mullen, RN, ANP, GNP

Mr. Y, a 60-year-old Caucasian male, presented to the clinic with complaints of fatigue, headache, and dry eyes but no vision changes. He stated that his symptoms started five months earlier but was only seeking medical attention because the headaches had increased in severity and frequency. He stated that he recently had undergone an extensive ophthalmology workup, the results of which were unremarkable. Mr. Y also reported reddening of his skin and purplish discoloration of his palms and soles of his feet. He lost about 10 pounds in three months and had poor appetite, early satiety, and gastric reflux, but denied nausea, vomiting, diarrhea, or constipation. He reported feeling "short winded" during periods of activity. Mr. Y reported having generalized pain, numbness, and tingling from his knees down to his feet and increasing abdominal girth with associated leg edema. He denied syncope, palpitations, chest pain, cough, fever, or chills or any head or spinal trauma or history of hypertension, congestive heart failure, diabetes, or stroke.

A physical examination revealed a man in a wheelchair appearing to be chronically ill with no acute distress. Vital signs were stable and within normal limits. He had alopecia and increased hair growth on his upper and lower extremities. His abdomen was distended, mildly firm, and nontender with a positive fluid wave. The edge of the liver was palpable with deep inspiration at the right costal margin; the spleen was palpable 12 cm below the left costal margin. Mr. Y's lower extremities had bilateral two-plus pitting edema and hyperpigmentation, his palms and soles had

purplish discoloration, and the remainder of his skin had a bronze appearance.

Laboratory data revealed the following abnormalities: hematocrit 30.2% (range 40%–52%), serum creatinine 1.6 mg/dl (range 0.5–1.4 mg/dl), blood urea nitrogen 30 mg/dl (range 7–21 mg/dl), calcium 7.9 mg/dl (range 8.9–10.4 mg/dl), and albumin 3 units/L (range 3.5–4.8 units/L). Thyroid function test revealed a thyroid stimulating hormone of 10.97 units/ml (range 0.4–4.5 units/ml) and free T4 of 0.5 ng/dl (range 0.8–1.5 ng/dl). A vascular endothelial growth factor (VEGF) level of 3,010 pg/ml (range 31–86 pg/ml) was elevated. The hepatitis panel was negative. A computed tomography scan of the abdomen revealed hepatosplenomegaly and ascites. Bone marrow aspiration and biopsy revealed 3% plasma cells without clonality. Serum protein electrophoresis revealed an immunoglobulin-A $\lambda$  (IgA $\lambda$ ) protein but no quantifiable monoclonal protein. X-ray bone survey showed no lytic lesions. An echocardiogram showed an ejection fraction of 60% with mild tricuspid regurgitation. A lumbar puncture was performed because of Mr. Y's complaints of headache. Cerebrospinal fluid obtained from the lumbar puncture revealed no white blood cells, one red blood cell, glucose of 89 mg/dl (range 50–80 mg/dl or about two-thirds of the blood glucose level), and protein of 55 mg/dl (range 15–45 mg/dl). Cerebrospinal fluid cytology and cultures were negative as was the computed tomography scan of the head. The rheumatoid panel and nerve conduction tests were unremarkable. Mr. Y was diagnosed with polyneuropathy, organomegaly,

endocrinopathy, monoclonal gammopathy, and skin changes (POEMS) syndrome.

### What is polyneuropathy, organomegaly, endocrinopathy, monoclonal gammopathy, and skin changes syndrome?

POEMS syndrome is a rare paraneoplastic syndrome secondary to a plasma cell dyscrasia. The acronym POEMS syndrome was first coined by Bardwick et al. in 1980. POEMS syndrome also is known as osteosclerotic myeloma, Crow-Fukase syndrome, Takatsuki syndrome, and PEP (plasma cell dyscrasia, endocrinopathy, polyneuropathy) syndrome. Important traits not included in the acronym include elevated levels of VEGF, sclerotic bone lesions, Castleman disease (a rare disorder characterized by benign lymph node tumors), papilledema, peripheral edema, ascites, effusions, thrombocytosis, polycythemia, fatigue, and clubbing (Dispenzieri, 2007). The prevalence and incidence rates of the syndrome are difficult to determine because of misdiagnosis and under reporting. The peak incidence of the POEMS syndrome is in patients aged 40–60, unlike multiple myeloma which has a peak incidence in patients aged 60–80 (Chan, 2006). The course of POEMS syndrome is chronic and patients typically survive for more than a decade in contrast to multiple myeloma, where life expectancy may be measured in months or a few years.

### What is the pathogenesis?

The pathogenesis of this multisystem disease is complex. The cause of POEMS syndrome is unknown, although chronic overproduction of proinflammatory and other

### Do You Have an Interesting Clinical Experience to Share?

Clinical Challenges provides readers with a forum to discuss creative clinical solutions to challenging patient care issues. Case studies or descriptions may be submitted with or without discussion or solutions. References, tables, figures, and illustrations can be included. Materials or inquiries should be directed to *Oncology Nursing Forum* Associate Editor Susan Moore, RN, MSN, ANP, AOCN®, at [smoore46@yahoo.com](mailto:smoore46@yahoo.com).

*Ellen C. Mullen, RN, ANP, GNP, is a nurse practitioner in the Lymphoma/Myeloma Department at the University of Texas M.D. Anderson Cancer Center in Houston. No financial relationships to disclose. Mention of specific products and opinions related to those products do not indicate or imply endorsement by the Oncology Nursing Forum or the Oncology Nursing Society.*

Digital Object Identifier: 10.1188/08.ONF.763-767

cytokines appears to be a major feature of the disorder, with microangiopathy, edema, effusions, and increased vascular permeability, neovascularization, polyneuropathy, pulmonary hypertension, leukocytosis, and thrombocytosis as possible examples of their effect (Dispenzieri, 2007). Interleukin-1 $\beta$  (IL-1 $\beta$ ), IL-6, and tumor necrosis factor- $\alpha$  (TNF- $\alpha$ ), reportedly are increased in association with the syndrome. Data have suggested that VEGF is an excellent candidate as a pathogenic factor in POEMS syndrome: It induces rapid and reversible increase in vascular permeability, is a growth factor for endothelial cells, and is considered important in angiogenesis. VEGF is expressed by osteoblasts and in bone tissue, macrophages, tumor cells (including plasma cells), and megakaryocytes or platelets (Dispenzieri et al., 2003). IL-1 $\beta$  and IL-6 have been shown to stimulate VEGF production. Increased VEGF also is postulated as a cause of neuropathy. Arimura (1999) studied the direct effects of VEGF on blood-nerve barrier function using an animal model and found that VEGF increased the microvascular permeability inducing endoneurial edema. Arimura believed that the increased permeability could allow serum components toxic to nerves, such as complement and thrombin, to induce further damage. In one study of human nerve biopsies of patients with POEMS syndrome, more than 50% of endoneurial blood vessels had narrowed or closed lumina with thick basement membranes, strong polyclonal immunoglobulin staining in the endoneurium, and thrombin-antithrombin complexes immunohistochemically (Saida, Kawakami, Ohta, & Iwamura, 1997). In a study of nerve biopsies by Scarlato et al. (2005), VEGF was highly expressed in blood vessels and some nonmyelinating Schwann cells.

### What are the risk factors?

Although the cause of POEMS syndrome is unknown, its development includes a diagnosis of plasma cell dyscrasia and presence of osteosclerotic lesions. Nakajima et al. (2007) proposed that plasma cells in osteosclerotic lesions are a major source of VEGF. Another risk factor is gender. POEMS syndrome is slightly more predominant in men than women with a ratio of 2.5:1 (Chan, 2006). Age also is a risk factor. The mean age of onset for men is 48 years and is 59 years for women. No genetic and racial associations have been strongly identified, but the syndrome is more prevalent in Japan (Chan).

### How is the syndrome diagnosed?

No single test can establish a POEMS syndrome diagnosis. The Mayo Clinic criteria (see Figure 1) for POEMS syndrome proposed that the diagnosis be made with the occurrence of a monoclonal lymphoproliferative disorder in the presence of a peripheral polyneuropathy, in addition to at least one of the following: sclerotic bone lesions, Castleman disease, or

VEGF elevation. To make the diagnosis, one minor criterion must be present: organomegaly (splenomegaly, hepatomegaly, or lymphadenopathy), volume overload (edema, pleural effusion, or ascites), endocrinopathy (adrenal, thyroid, pituitary, gonadal, parathyroid, and pancreatic), skin changes (hyperpigmentation, hypertrichosis, plethora, hemangiomas, and leukonychia), papilledema, or thrombocytosis or polycythemia (Dispenzieri, 2007). The prevalence of each of the presentations except polyneuropathy and monoclonal plasma cell proliferative disorder varies (see Figure 2).

The diagnostic workup of POEMS syndrome depends on the demonstration of a monoclonal immunoglobulin in the serum or urine or increased numbers of monoclonal plasma cells in a biopsy specimen from the osteosclerotic lesion or the bone marrow (Rathakrishnan, Liu, Chen, & Ong, 2007). Bone marrow usually contains more than 5% plasma cells, and when clonal cells are found they are almost always monoclonal  $\lambda$ . The M-protein in the serum and urine usually is present in a low concentration (rarely more than 3.0 g/dl) and may be easily overlooked unless immunofixation is performed on both serum and a 24-hour urine collection (Dispenzieri, 2007). The M-protein usually is IgG or IgA and typically of the  $\lambda$  type. Lymph node biopsy is indicated in patients with lymphadenopathy and, in most patients, demonstrates findings of Castleman disease.

VEGF levels are almost always elevated in patients with active POEMS syndrome (Gutgemann, Stevens, Loftus, Schmidt-Wolfs, & George, 2008), one of the major features included in the Mayo Clinic criteria. Other cytokine levels, such as IL-1 $\beta$ , TNF- $\alpha$ , and IL-6, often are increased. The symptoms of POEMS syndrome correlate with changes in VEGF levels. Possible sources of VEGF in POEMS syndrome are osteosclerotic lesions, plasma cells, platelets, tumor cells, endothelial cells, or nonmyelinating Schwann cells (Nakajima et al., 2007). Cerebrospinal fluid protein levels and VEGF are elevated in virtually all patients with POEMS syndrome.

Radiographic tests are valuable in establishing a POEMS syndrome diagnosis. A bone survey should be included in the diagnostic workup to evaluate osteosclerotic lesions, which occur in about 95% of patients (Gutgemann et al., 2008). The lesions can be subtle and easily confused with fibrous dysplasia or a vertebral hemangioma. Pulmonary function tests, a chest x-ray, and an echocardiogram should be performed if patients present with cardiopulmonary symptoms.

A detailed physical examination is critical, with emphasis placed on the fundoscopic examination for papilledema, evaluation for organomegaly, examination of the skin, and evaluation for the presence of peripheral edema, pleural or pericardial effusion, ascites, clubbing, congestive heart failure, and cardio-

### Major Criteria

- Polyneuropathy
- Monoclonal plasma cell-proliferative disorder (almost always  $\lambda$ )
- Sclerotic bone lesions
- Castleman disease
- Vascular endothelial growth factor elevation.

### Minor Criteria

- Organomegaly (splenomegaly, hepatomegaly, or lymphadenopathy)
- Extravascular volume overload (edema, pleural effusion, or ascites)
- Endocrinopathy (adrenal, thyroid<sup>a</sup>, pituitary, gonadal, parathyroid, pancreatic<sup>a</sup>)
- Skin changes (hyperpigmentation, hypertrichosis, glomeruloid hemangiomas, plethora, acrocyanosis, flushing, white nails)
- Papilledema
- Thrombocytosis or polycythemia<sup>b</sup>

### Other Signs and Symptoms

- Clubbing
- Weight loss
- Hyperhidrosis
- Pulmonary hypertension/restrictive lung disease
- Thrombotic diatheses
- Diarrhea
- Low vitamin B<sub>12</sub> level

### Possible Associations

- Arthralgia
- Cardiomyopathy (systolic dysfunction)
- Fever

<sup>a</sup> Because of the high prevalence of diabetes mellitus and thyroid abnormalities, this diagnosis alone is not sufficient to meet this minor criterion.

<sup>b</sup> Anemia or thrombocytopenia is distinctively unusual in this syndrome unless Castleman disease is present.

## Figure 1. Mayo Clinic Criteria for the Diagnosis of Polyneuropathy, Organomegaly, Endocrinopathy, Monoclonal Gammopathy, and Skin Changes Syndrome

Note. From "POEMS Syndrome," by A. Dispenzieri, 2007, *Blood Reviews*, 21(6), p. 287. Copyright 2008 by Elsevier Limited. Reprinted with permission.

myopathy. The skin changes are described as hyperpigmentation of the skin, which is the most common, and appearance of coarse black hair on the extremities. Other skin changes include skin thickening, rapid accumulation of glomeruloid angiomas (a specific marker of POEMS syndrome), flushing, dependent rubor, or acrocyanosis (Colaco, Miller, Ruben, Fogarty, & Fox, 2008).

A baseline complete blood count should be obtained. Thrombocytosis and polycythemia are common findings with POEMS syndrome. Anemia and thrombocytopenia are not characteristic of the syndrome unless Castleman disease is present (Dispenzieri, 2007). A

complete metabolic panel and an assessment of renal function should be included. Hypercalcemia and renal insufficiency are rarely present; however, renal disease is more likely to occur in patients who have coexisting Castleman disease. The workup for endocrinopathy, which includes thyroid abnormalities, glucose metabolism abnormalities, hypogonadism, and adrenal insufficiency, should be included in the diagnostic workup. Hypogonadism is the most common endocrine abnormality associated with POEMS syndrome (Kyle & Rajkumar, 2007).

Neuropathy is the most common feature of POEMS syndrome, necessitating performance of nerve conduction studies and electromyography. The tests show slowing of nerve conduction, prolonged distal latencies, and severe attenuation of compound muscle action potentials (Kyle & Rajkumar, 2007). A biopsy of the sural nerves demonstrates polyneuropathy with prominent demyelination as well as features of axonal degeneration that are similar to the findings of patients with chronic inflammatory demyelinating polyradiculoneuropathy, putting it high on the list of differential diagnoses.

### Can the syndrome be prevented?

The cause of POEMS syndrome is unknown and the risk factors are very few; therefore, measures to prevent the development of POEMS syndrome are limited. Because patients with plasma cell dyscrasia are at risk to develop the syndrome, close monitoring of those patients is important. Patients who have osteosclerotic lesions should be treated promptly. If development of POEMS syn-

drome cannot be prevented, patient outcome may be improved by making the diagnosis in a timely fashion to prevent irreversible neurologic disability. A strong association exists between POEMS syndrome and Castleman disease; therefore, the correct diagnosis must be established early to initiate appropriate treatment (Kyle & Rajkumar, 2007). Additional features typically arise over time if treatment is unsuccessful or if the diagnosis is delayed (Dispenzieri, 2007).

### How is the syndrome managed?

Because the pathogenesis of POEMS syndrome remains poorly understood, no standard therapy exists (Dispenzieri et al., 2003). Treatment is aimed at the underlying plasma cell dyscrasia. No randomized controlled trials have taken place with patients with POEMS syndrome and most of the information about benefits of therapy has been derived retrospectively and anecdotally (Dispenzieri & Gertz, 2005). Radiation therapy, chemotherapy, corticosteroids, and hematopoietic stem cell transplantation have been shown as effective treatments for POEMS syndrome.

External beam radiation is considered to be first-line therapy in patients with a single dominant osteosclerotic lesion. Multiple osteosclerotic lesions in a limited area can be treated with radiation as well. Dispenzieri and Gertz (2005) and others have shown that systemic and skin symptoms tend to respond within one month following radiation therapy. According to Dispenzieri and Gertz, more than 50% of patients treated with radiation will respond and patients have excellent sur-

vival. In addition, neurologic improvement usually is observed after three to six months and will continue to improve for two to three years following radiation therapy.

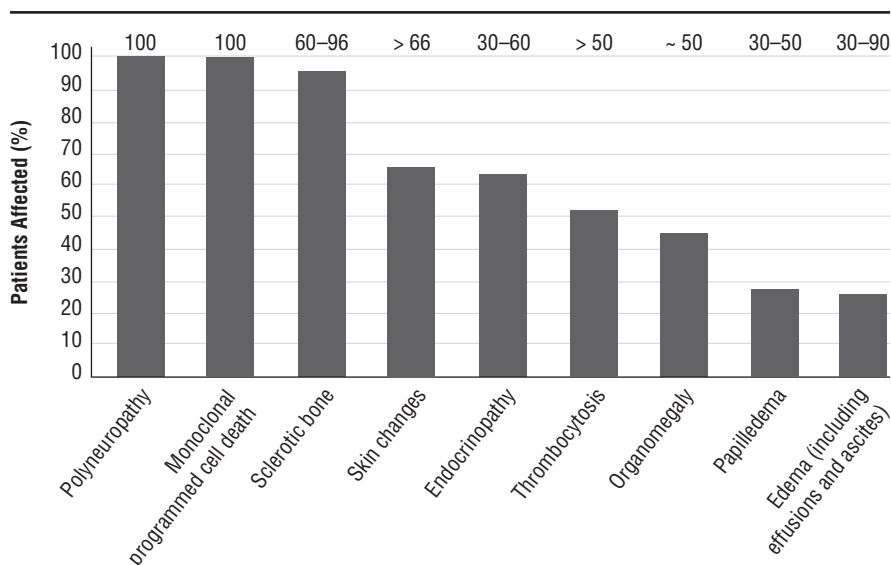
Systemic therapy is warranted if widespread osteosclerotic lesions or diffuse bone marrow plasmacytosis are present. Dispenzieri (2007) demonstrated that melphalan and prednisone produced improvement in 21 of 48 (44%) patients studied. Melphalan, an alkylating agent, is among the most effective agents against plasmaproliferative disorders. The optimal duration of therapy for POEMS syndrome has not been established, but based on experience with multiple myeloma, 12–24 months of treatment is reasonable. Long-term use of melphalan can lead to myelodysplastic syndrome or acute leukemia. For patients considered to be candidates for peripheral stem cell transplantation, melphalan-containing regimens should be avoided until after stem cell harvest. Cyclophosphamide is another alkylating agent that can control POEMS syndrome in some patients and can be given as a single agent or in combination with prednisone. Most reports are from small studies, but improvement in organomegaly and nerve conduction studies have been documented (Dispenzieri & Gertz, 2005).

Stem cell transplantation seems to be a promising treatment for POEMS syndrome. Laurenti et al. (2008) treated four patients affected by POEMS syndrome with first-line chemotherapy and autologous peripheral blood stem cell transplantation. After a median follow-up of 40.5 months, all patients were alive with slow but progressive improvement in neurologic disease, skin changes, performance status, and without evidence of clonal plasmacytosis and organomegaly. Data have shown neuropathy improved and VEGF levels decreased after transplantation. Improvement of neuropathy with stem cell transplantation occurs over time. As with radiation therapy and other chemotherapy, improvement of the peripheral neuropathy occurs over months and years. According to Dispenzieri et al. (2003), the transplantation-related morbidity and mortality are higher in patients with POEMS syndrome than patients with myeloma.

Surgical excisions of sclerotic lesions have been reported but are not considered standard treatment because of associated morbidity. The tumor bed generally is irradiated if an excisional biopsy is performed (Dispenzieri & Gertz, 2005). The role of plasmapheresis in the treatment of POEMS syndrome has not been proven strongly. The studies that have been done did not look at plasmapheresis alone, but rather treatments that included corticosteroids or other therapies (Dispenzieri, 2007).

IV immunoglobulin is not considered an effective treatment for POEMS syndrome. A small number of reports claim effectiveness, but the studies included simultaneous use of other treatments (Rathakrishnan et al., 2007).

Thalidomide has been proposed as a treatment because of its anti-VEGF and antitumor



Note. The bars represent the percent of patients with feature in the Mayo Series. The numbers over the bars represent the percent of patients with feature in three other large series.

### Figure 2. Percent of Patients With Feature at Diagnosis

Note. From "POEMS Syndrome," by A. Dispenzieri, 2007, *Blood Reviews*, 21(6), p. 288. Copyright 2008 by Elsevier Limited. Reprinted with permission.



necrotic factor effects (Dispenzieri & Gertz, 2005). However, it causes peripheral neuropathy and fluid retention. In contrast, lenalidomide has a lower risk of peripheral neuropathy. Other drugs that have been used to treat POEMS syndrome include bevacizumab (Badros, Porter, & Zimrin, 2005; Samaras et al., 2007), all-trans-retinoic acid (Authier, Belec, & Levy, 1996), tamoxifen (Enevoldson & Harding, 1992), ticlopidine (Matsui et al., 2004), and thalidomide (Sinisalo, Hietaharju, Sauranan, & Wirta, 2004). An inadequate amount of randomized phase II or III data exist to conclude that these agents are effective in the treatment of POEMS syndrome because most of the information reporting benefit is anecdotal.

Treatment of POEMS syndrome requires a multidisciplinary approach. As a result of the physical limitations patients experience from severe neuropathy, physical and occupational therapy are essential to maintain flexibility and assist in lifestyle management. Patients who experience cardiopulmonary symptoms will require supplemental oxygen. Symptom management is very important, particularly for patients with ascites, edema, and effusions. Patients can benefit from thoracentesis and paracentesis to relieve any discomfort. Emphasizing to patients the importance of follow-up with their oncologist is critical. Long-term prognosis of POEMS syndrome after remission is uncertain. About 50% of patients with POEMS syndrome succumb to multisystem organ failure within eight years of onset of POEMS syndrome (Hyett, 2003). Patients should adhere to their scheduled follow-ups to properly detect and manage early signs of relapse.

**Author Contact:** Ellen C. Mullen, RN, ANP, GNP, can be reached at ellenmullen111@yahoo.com, with copy to editor at ONF Editor@ons.org.

## References

- Arimura, K. (1999). Increased vascular endothelial growth factor (VEGF) is causative in Crow-Fukase syndrome. *Rinsho Shinkeigaku Clinical Neurology*, 39(1), 84–85.
- Authier, F.J., Belec, L., & Levy, Y. (1996). All trans-retinoic acid in POEMS syndrome. Therapeutic effect associated with decreased circulating levels of proinflammatory cytokines. *Arthritis and Rheumatism*, 39(8), 1423–1426.
- Badros, A., Porter, N., & Zimrin, A. (2005). Bevacizumab therapy for POEMS syndrome. *Blood*, 106(3), 1135.
- Bardwick, P.A., Zvaifler, N.J., Gill, G.N., Newman, D., Greenway, D.L., & Resnick, D.L. (1980). Plasma cell dyscrasia with polyneuropathy, organomegaly, endocrinopathy, M-protein, and skin changes: The POEMS syndrome. *Medicine*, 59(4), 311–322.
- Chan, J. (2006). POEMS syndrome. Retrieved May 3, 2008, from <http://www.emedicine.com/derm/TOPICT771.htm>
- Colaco, S., Miller, T., Ruben, B., Fogarty, P., & Fox, L. (2008). IgM- $\lambda$  paraproteinemia with associated cutaneous lymphoplasmacytic infiltrate in a patient who meets diagnostic criteria for POEMS syndrome. *Journal of the American Academy of Dermatology*, 58(4), 671–675.
- Dispenzieri, A. (2007). POEMS syndrome. *Blood Reviews*, 21(6), 285–299.
- Dispenzieri, A., & Gertz, M. (2005). Treatment options for POEMS syndrome. *Expert Opinion on Pharmacotherapy*, 6(6), 945–953.
- Dispenzieri, A., Kyle, R., Lacy, M., Rajkumar, V., Therneau, T., Larson, D., et al. (2003). POEMS syndrome: Definitions and long-term outcome. *Blood*, 101(7), 2496–2506.
- Enevoldson, T.P., & Harding, A.E. (1992). Improvement in the POEMS syndrome after administration of tamoxifen. *Journal of Neurology, Neurosurgery, and Psychiatry*, 55(1), 71–72.
- Gutgemann, I., Stevens, K., Loftus, D., Schmidt-Wolfs, I., & George, J. (2008). VEGF and osteosclerosis in POEMS syndrome. *Annals of Hematology*, 87(3), 243–245.
- Hyett, J. (2003). What's wrong with this patient? *RN*, 66(11), 45–48.
- Kyle, R., & Rajkumar, S. (2007). POEMS syndrome (osteosclerotic myeloma). Retrieved April 4, 2008, from <http://www.uptodate.com/patients/content/topic.do?topicKey=plasma/7801>
- Laurenti, L., De Matteis, S., Sabatelli, M., Conte, A., Chiusolo, P., Sora, F., et al. (2008). Early diagnosis followed by front-line autologous peripheral blood stem cell transplantation for patients affected by POEMS syndrome. *Leukemia Research*, 32(8), 1309–1312.
- Matsui, H., Uda, K., Kubori, T., Oda, M., Nishinaka, M., & Kameyama, M. (2004). POEMS syndrome demonstrating VEGF decrease by ticlopidine. *Internal Medicine*, 43(11), 1082–1083.
- Nakajima, H., Ishida, S., Furutama, D., Sugino, M., Kimura, F., Yokote, T., et al. (2007). Expression of vascular endothelial growth factor by plasma cells in the sclerotic bone lesions of a patient with POEMS syndrome. *Journal of Neurology*, 254(4), 531–533.
- Rathakrishnan, R., Liu, T., Chen, Y.C., & Ong, B. (2007). POEMS syndrome—A case for more aggressive treatment. *Annals of the Academy of Medicine*, 36(6), 435–437.
- Saida, K., Kawakami, H., Ohta, M., & Iwamura, K. (1997). Coagulation and vascular abnormalities in Crow-Fukase syndrome. *Muscle and Nerve*, 20(4), 486–492.
- Samaras, P., Bauer, S., Stenner-Liewen, F., Steiner, R., Zweifel, M., Renner, C., et al. (2007). Treatment of POEMS syndrome with bevacizumab. *Haematologica*, 92(10), 1438–1439.
- Scarlato, M., Previtali, S., Carpo, M., Pareyson, D., Briani, C., Del Bo, R., et al. (2005). Polyneuropathy in POEMS syndrome. *Brain*, 128(8), 1911–1920.
- Sinisalo, M., Hietaharju, A., Sauranan, J., & Wirta, O. (2004). Thalidomide in POEMS syndrome: Case report. *American Journal of Hematology*, 76(1), 66–68.

## Clinical Highlights: Polyneuropathy, Organomegaly, Endocrinopathy, Monoclonal Gammopathy, and Skin Changes (POEMS) Syndrome

### Definition

Polyneuropathy, organomegaly, endocrinopathy, monoclonal gammopathy, and skin changes (POEMS) syndrome is a rare paraneoplastic syndrome secondary to a plasma cell dyscrasia. To make the diagnosis of POEMS syndrome based on the revised Mayo Clinic criteria (Dispenzieri, 2007), the presence of a monoclonal plasma cell dyscrasia and osteosclerotic lesions, peripheral neuropathy plus one other major criteria (Castleman disease or elevated vascular endothelial growth factor [VEGF] levels), and one or more minor criteria are required. Minor criteria include organomegaly, volume overload, endocrinopathy, skin changes, papilledema, thrombocytosis,

or polycythemia (Dispenzieri). Associated signs and symptoms may include clubbing, weight loss, hyperhidrosis, pulmonary hypertension or restrictive lung disease, thrombotic diatheses, diarrhea, low vitamin B<sub>12</sub> level, arthralgias, cardiomyopathy, and fever. The number of POEMS features present does not affect survival although fingernail clubbing and extravascular volume overload (i.e., edema, effusions, and ascites) were significantly associated with a shorter overall survival (Dispenzieri et al., 2003).

### Pathophysiology

Overproduction of proinflammatory and other cytokines, such as VEGF, appears to be a major feature of this disorder (Dispenzieri, 2007). Increased VEGF levels result

in microangiopathy, edema, effusions, and increased vascular permeability, neovascularization, polyneuropathy, pulmonary hypertension, leukocytosis, and thrombocytosis. Elevations of other cytokines such as interleukin-1 $\beta$  (IL-1 $\beta$ ), IL-6, and tumor necrosis factor- $\alpha$  (TNF- $\alpha$ ), have been noted. Manifestations of POEMS syndrome might be regarded as the result of a marked activation of these cytokines associated with a weak or decreased TNF- $\alpha$ 1 antagonistic reaction. Elevated levels of VEGF were noted to decrease significantly in patients with POEMS syndrome after therapy.

### Risk Factors

Risk factors for POEMS syndrome include diagnosis of plasma cell dyscrasia,

elevated VEGF levels, and osteosclerotic lesions. Other risk factors are advancing age and male gender. No racial associations have been strongly identified, but the syndrome is more prevalent in Japan (Chan, 2006).

## Prevention

Because patients diagnosed with plasma cell dyscrasia are at risk for developing POEMS syndrome, close monitoring and attention to patients' signs and symptoms can help prevent its development. Diagnosing POEMS syndrome early and prompt treatment can help prevent its debilitating complications (Dispenzieri, 2007).

## Clinical Findings

The clinical manifestations of POEMS syndrome are variable. All patients have peripheral neuropathy and a monoclonal plasma cell disorder. In addition, almost all patients have either osteosclerotic myeloma (solitary or multiple) or Castleman disease (Kyle & Rajkumar, 2007). The prevalence of other manifestations such as organomegaly, endocrinopathy, and skin changes varies.

**Polyneuropathy:** Symptoms of peripheral neuropathy, secondary to peripheral sensory and motor nerve demyelination and axonal degeneration, usually dominate the clinical picture. Symptoms begin in the feet and consist of tingling, paresthesias, and coldness with subsequent motor involvement. Both are distal and symmetric, and progressive with a gradual proximal spread (Kyle & Rajkumar, 2007). Severe weakness eventually occurs, leading to inability to climb stairs, rise from a chair, or firmly grasp objects.

**Organomegaly:** Organ enlargement occurs in most POEMS cases. Commonly effected are the lymph nodes, spleen, and liver (Hyett, 2003).

**Endocrinopathy:** Endocrinopathy is a central but poorly understood feature of POEMS (Dispenzieri, 2007). The four major endocrine axes (gonadal, thyroid, glucose, and adrenal) can be affected. Abnormal levels of hormones in patients with POEMS syndrome may lead to hypothyroidism, gynecomastia, and adrenal insufficiency.

**Monoclonal gammopathy:** The M-protein usually is immunoglobulin G (IgG) or IgA and almost always of the  $\lambda$  type. The M-protein in the serum and urine is almost always present in a low concentration (rarely more than 3.0 g/dl) and may be easily overlooked unless immunofixation is performed on both serum and a 24-hour urine collection (Dispenzieri, 2007).

**Skin changes:** Hyperpigmentation is the most common skin change seen. Coarse black hair may appear on the extremities. Other skin changes include skin thickening, flushing, dependent rubor or acrocyanosis, white nails, and clubbing. Pitting edema of the lower extremities also is common and

excessive sweating has been reported. Multiple angiomas, including cherry, lobular, and glomeruloid, occur in about a third of patients and tend to be distributed over the trunk and extremities (Colaco, Miller, Ruben, Fogarty, & Fox, 2008). Glomeruloid hemangiomas, histologically distinctive cutaneous angiomas associated with POEMS syndrome, have been reported as a specific marker and are present in 24%–44% of patients. They appear as multiple red-purple lesions occurring on the trunk and proximal limbs and have not been reported in patients without POEMS syndrome (Weimer, Norton, & Gutmann, 2006).

## Differential Diagnosis

- Chronic inflammatory demyelinating polyneuropathy
- Monoclonal gammopathy of undetermined significance and associated peripheral neuropathy (Dispenzieri, 2007)
- Multiple myeloma also is included in the differential diagnosis because of the presence of polyneuropathy. In rare instances, multiple myeloma can present with diffuse osteosclerotic bone lesions (Kyle & Rajkumar, 2007).
- Solitary plasmacytoma of bone may have a small amount of a monoclonal protein in the serum or urine.
- Waldenstrom macroglobulinemia is a lymphoplasmacytic lymphoma with the additional presence of an IgM monoclonal gammopathy and may be complicated by polyneuropathy. In Waldenstrom, infiltration of the bone marrow or lymph nodes with abnormal lymphoplasmacytic cells is present. Those abnormal cellular infiltrates, along with absence of other minor criteria for POEMS syndrome, should distinguish Waldenstrom from POEMS syndrome (Kyle & Rajkumar, 2007).
- Primary amyloidosis is another differential diagnosis because it is a plasma cell disorder often associated with monoclonal gammopathy, skin lesions, and polyneuropathy. Biopsy of the involved tissue will show presence of typical amyloid fibrils.
- Cryoglobulinemia (mixed cryoglobulinemia type II) is associated with peripheral neuropathy and the presence of a monoclonal gammopathy. The diagnosis rests principally in the laboratory demonstration of serum cryoglobulins.

## Treatment

Treatments include chemotherapy, steroids, radiation therapy, and stem cell transplantation. Alkylating agents, such as melphalan or cyclophosphamide, can be used. Corticosteroids with chemotherapy have been shown to be effective. Radiation therapy is most successful if only one or two dominant lesions are present. Some patients with solitary osteosclerotic lesions respond to surgical excision (Rathakrishnan, Liu, Chen, & Ong, 2007). For patients who do not

respond to treatment, high-dose chemotherapy and stem cell transplantation should be considered; however, first-line autologous stem cell transplantation has shown efficacy (Laurenti et al., 2008). For patients who are candidates for stem cell transplantation, melphalan-containing regimens should be avoided until after the stem cell harvest.

## Nursing Implications

Symptom management is important in the care of patients with POEMS syndrome. Neuropathy is a major presentation of this syndrome, making pain control and prevention of disability top priorities. Physical and occupational therapy are strongly recommended. Patients may present with cardiopulmonary symptoms; therefore, promoting adequate oxygenation is essential. Patients with ascites can benefit from paracentesis. Because skin changes and anasarca can result in skin breakdown, particular attention to skin is important. Long-term prognosis of POEMS syndrome after remission is uncertain. About 50% of all patients with POEMS syndrome succumb to multisystem organ failure within eight years of the onset (Hyett, 2003). Patients should adhere to their scheduled follow-ups for prompt detection and management of early signs of relapse.

## References

- Chan, J. (2006). POEMS syndrome. Retrieved May 3, 2008, from <http://www.emedicine.com/derm/TOPICT771.htm>
- Colaco, S., Miller, T., Ruben, B., Fogarty, P., & Fox, L. (2008). IgM- $\lambda$  paraproteinemia with associated cutaneous lymphoplasmacytic infiltrate in a patient who meets diagnostic criteria for POEMS syndrome. *Journal of the American Academy of Dermatology*, 58(4), 671–675.
- Dispenzieri, A. (2007). POEMS syndrome. *Blood Reviews*, 21(6), 285–299.
- Dispenzieri, A., Kyle, R., Lacy, M., Rajkumar, V., Therneau, T., Larson, D., et al. (2003). POEMS syndrome: Definitions and long-term outcome. *Blood*, 101(7), 2496–2506.
- Hyett, J. (2003). What's wrong with this patient? *RN*, 66(11), 45–48.
- Kyle, R., & Rajkumar, S. (2007). POEMS syndrome (osteosclerotic myeloma). Retrieved April 4, 2008, from <http://www.uptodate.com/patients/content/topic.do?topicKey=plasma/7801>
- Laurenti, L., De Matteis, S., Sabatelli, M., Conte, A., Chiusolo, P., Sora, F., et al. (2008). Early diagnosis followed by front-line autologous peripheral blood stem cell transplantation for patients affected by POEMS syndrome. *Leukemia Research*, 32(8), 1309–1312.
- Rathakrishnan, R., Liu, T., Chen, Y.C., & Ong, B. (2007). POEMS syndrome—A case for more aggressive treatment. *Annals of the Academy of Medicine*, 36(6), 435–437.
- Weimer, T., Norton, A., & Gutmann, L. (2006). Glomeruloid hemangioma: A marker for POEMS. *Neurology*, 66(3), 453–454.